31st European Congress of Pathology

Pathology is Nice

7 – 11 September 2019, Nice, France

European Society of Pathology

Slide seminar case

Esther Rossi MD PhD MIAC

Division of Anatomic Pathology and Cytology

Catholic University of Sacred Heart

Rome, Italy

Gemelli

Fondazione Policlinico Universitario A. Gemelli
Università Cattolica del Sacro Cuore

IT ‘S A MATTER OF….

CASE HISTORY

29 y/o woman

3.2 cm right thyroid nodule in 2018

Previous FNAC diagnosed as “possible mesenchymal neoplasm positive for vimentin” in 2012

FNAC processed by LBC and Conventional cytology

Cytological Findings

Scant colloid

Cellular smears

SEVERAL isolated and few small loosely groups of follicular cells with spindle-elongated features and mild/focal nuclear irregularities

Eosinophilic granular cytoplasm and scant/absent cytoplasm in several cells

Round-oval nuclear shape with spindle-elongated features

Chromatin clearing and perinuclear clearing

Few nuclear grooves

Few nuclear inclusions

Focally, hyaline-globular stromal component

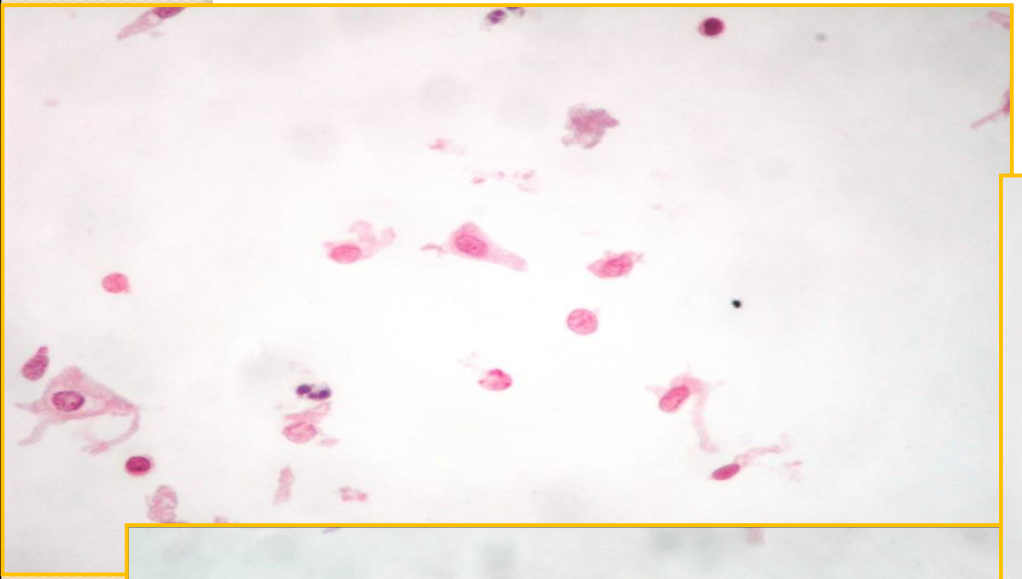

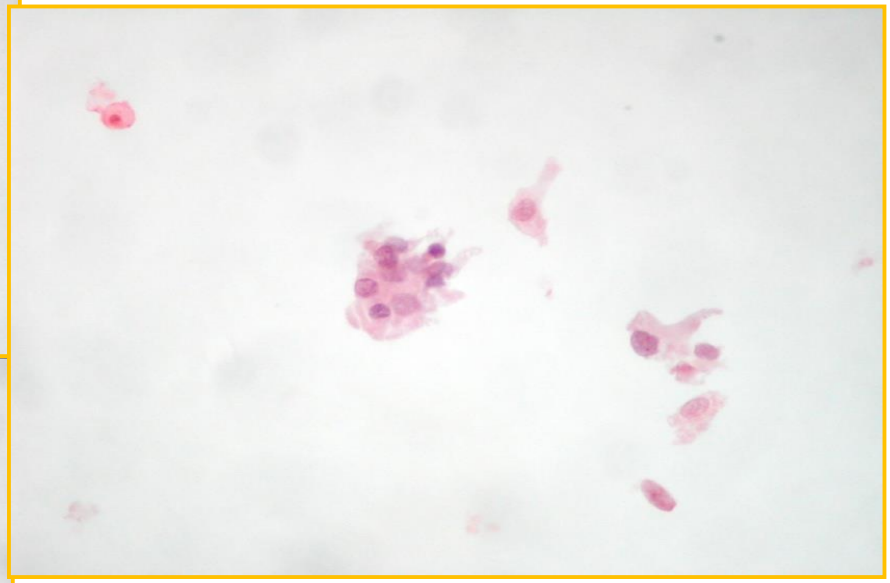

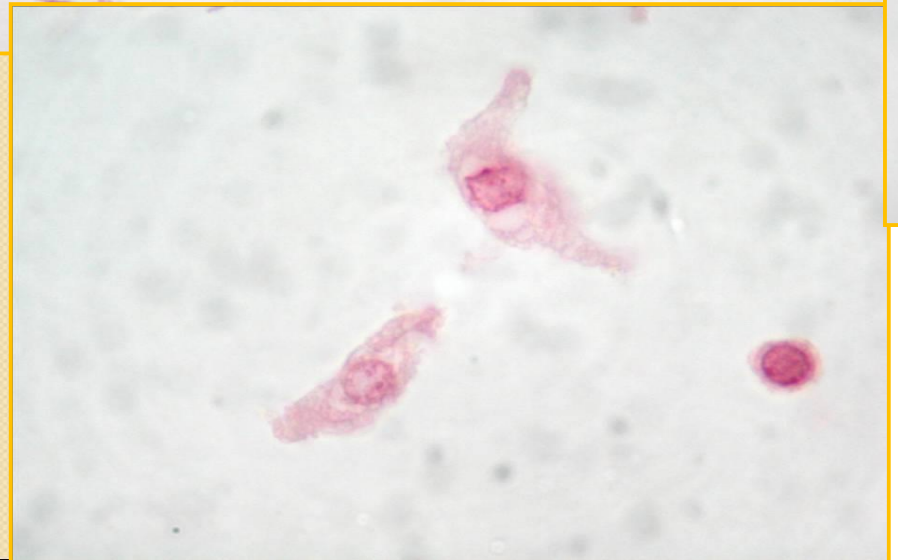

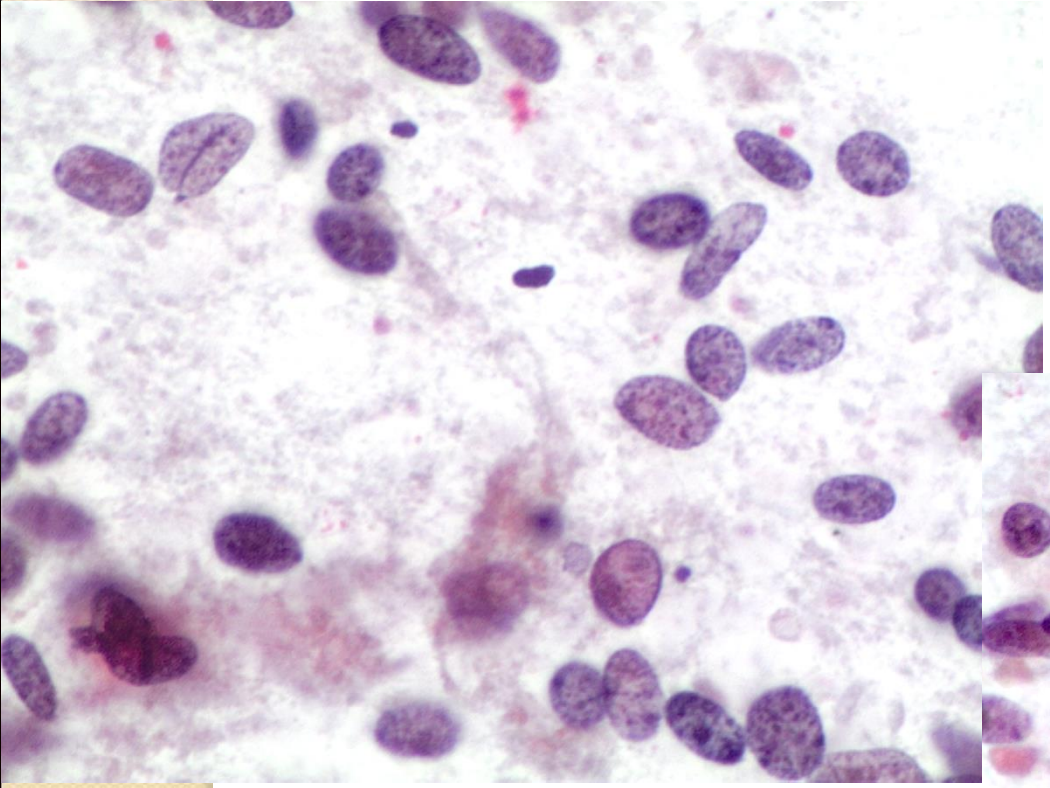

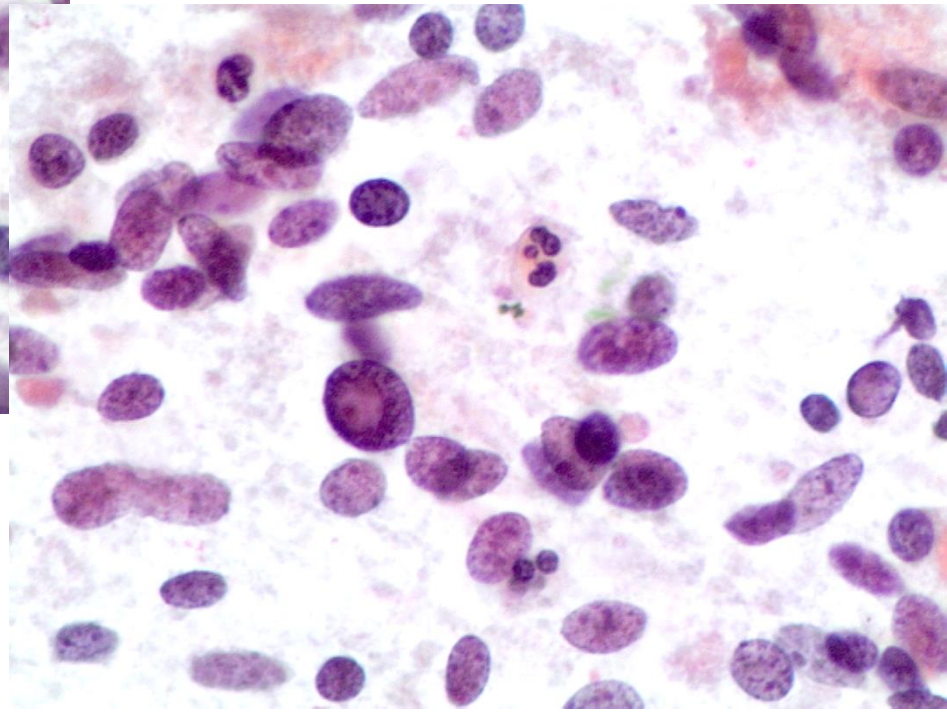

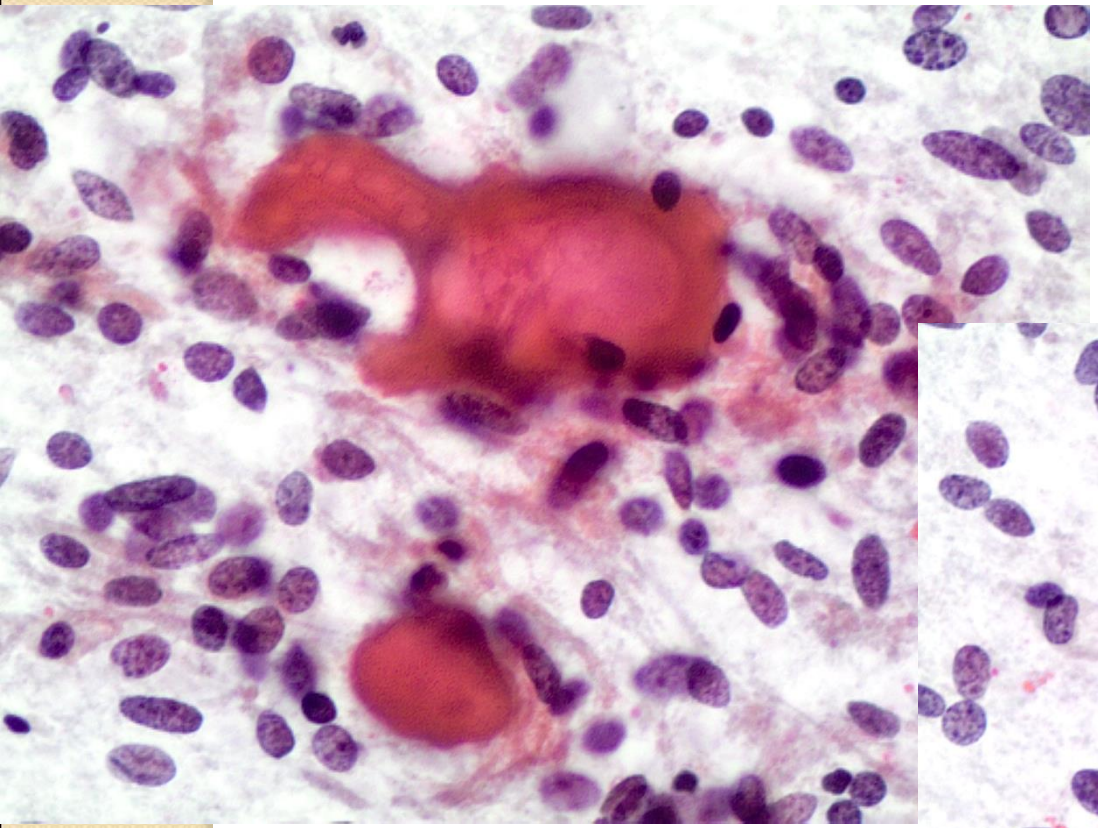

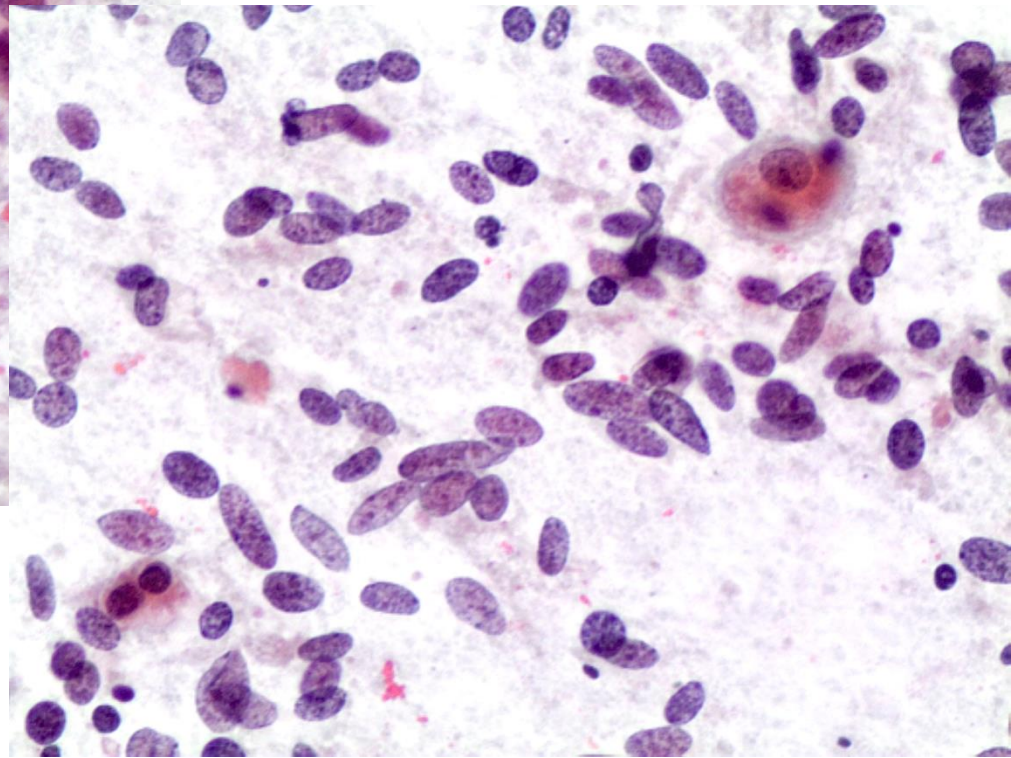

What could I morphologically conclude?

A diagnostic dilemma

POSSIBLE DIFFERENTIAL DIAGNOSIS IN PRESENCE OF SPINDLE-ELONGATED FEATURES..and not only!

BENIGN

1. Hashimoto Thyroiditis
2. Riedel Thyroiditis
3. Effect of FNAB
4. Follicular neoplasm with spindle areas
5. Clear cell oxyphilic neoplasm
6. Hyalinizing Trabecular Tumor
7. Solitary fibrous tumor
8. Smooth muscle tumor

MALIGNANT

1. Papillary Thyroid carcinoma
2. Medullary Thyroid carcinoma
3. Poorly differentiated and/or anaplastic cancer
4. Metastatic tumor

PAPILLARY CARCINOMA

- May occur with multiple nodules
- High cellularity
- Follicular clusters or papillary structures
- Medium to large cells with clearing, nuclear pseudoinclusions, grooves
- Possible squamoid metaplasia (focal finding)
- Sometimes bundles of sclerotic tissue

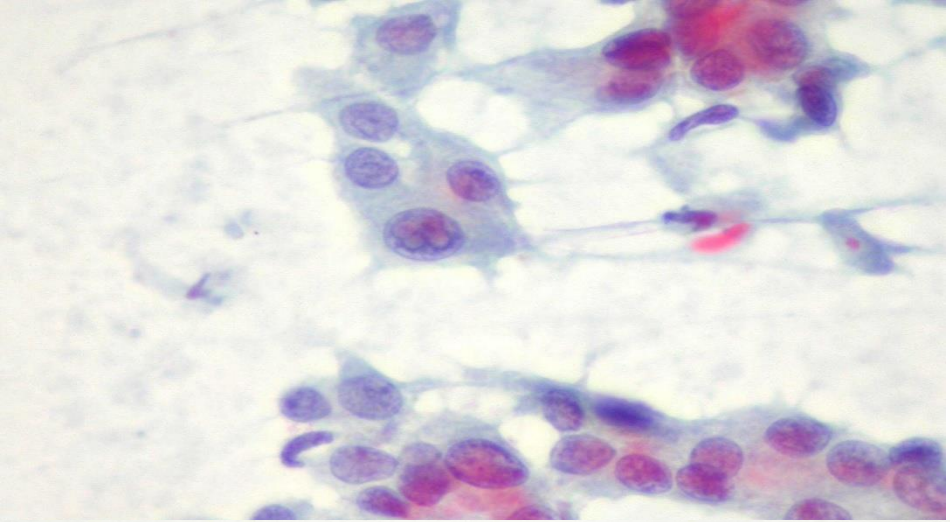

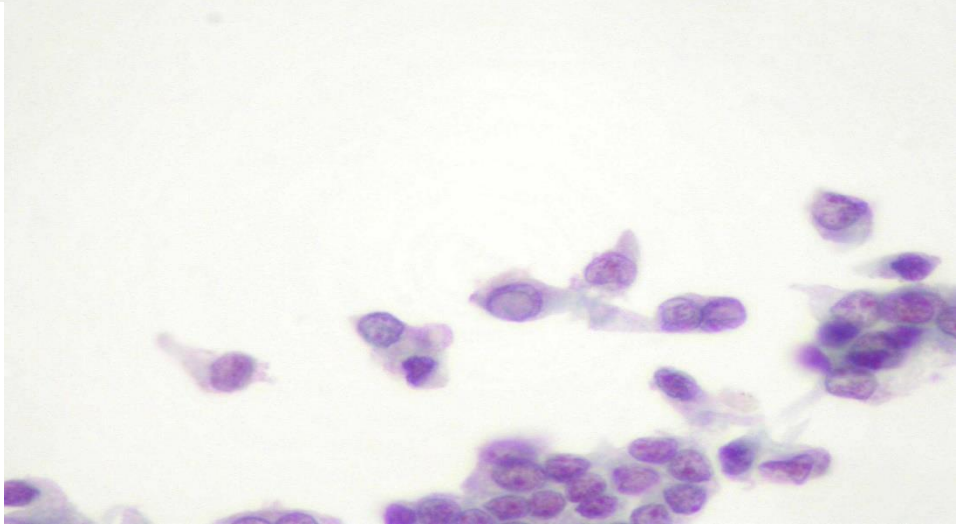

MEDULLARY THYROID CARCINOMA

- Multiple small nodules are frequently observed
- May present with either biphasic or monophasic pattern
- Lack of follicular structures
- Wide range of cellular types (including large, plasmacytoid, spindle-shaped and signet-ring cells)
- Fibrous tissue admixed with cellular clusters
- Amyloid is often present

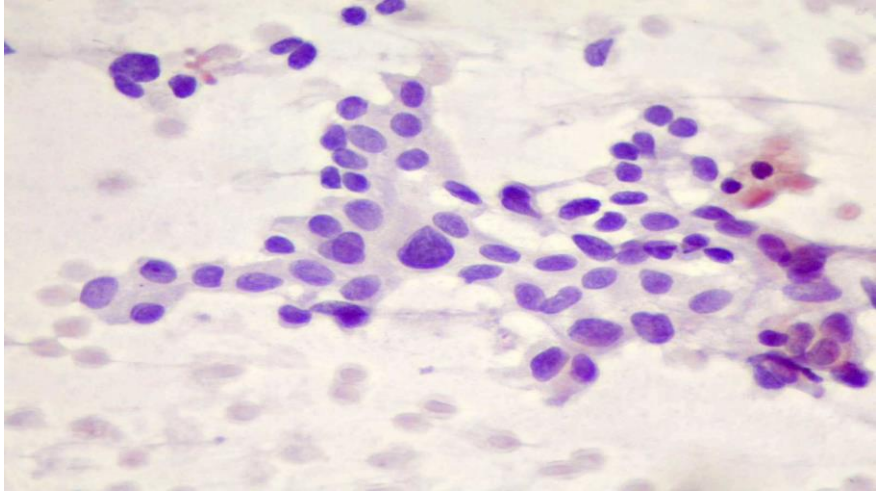

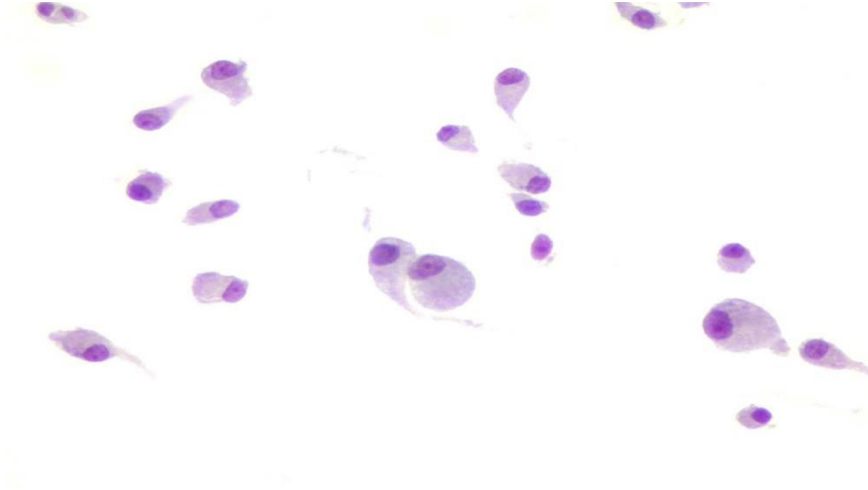

PDTC

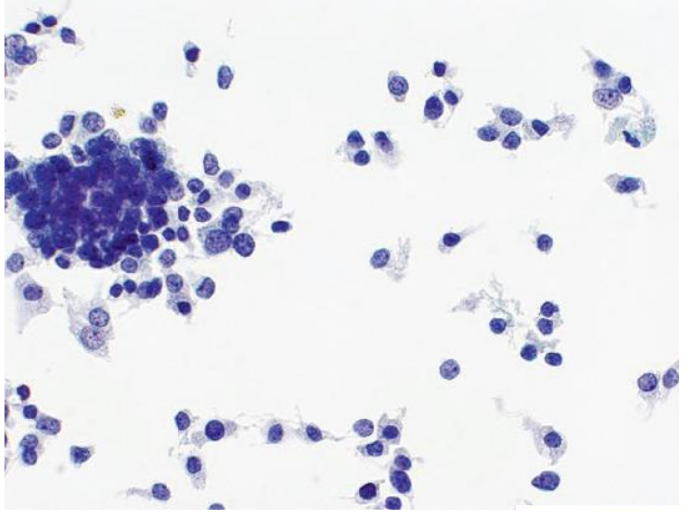

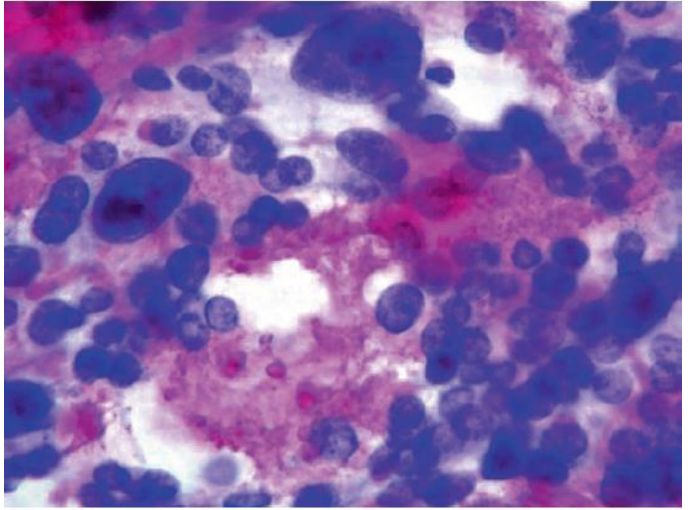

Criteria

Cellular preparations display an insular, solid, or trabecular cytoarchitecture (Figs. 10.1, 10.2, 10.3, and 10.4).

There is a uniform population of malignant follicular cells with scant cytoplasm (sometimes plasmacytoid) (Fig. 10.5) or with oncocytic features (Fig. 10.6).

The cells have a high nuclear/cytoplasmic (N/C) ratio with variable nuclear atypia (Figs. 10.7 and 10.8).

Colloid is scant.

Apoptosis and mitotic activity are present (Fig. 10.9).

Necrosis is often present (Fig. 10.10).

In liquid-based cytology, PDTC exhibits the same cytomorphology, characterized by a population of cells with a high N/C ratio and focal nuclear atypia (Figs. 10.2 and 10.5).

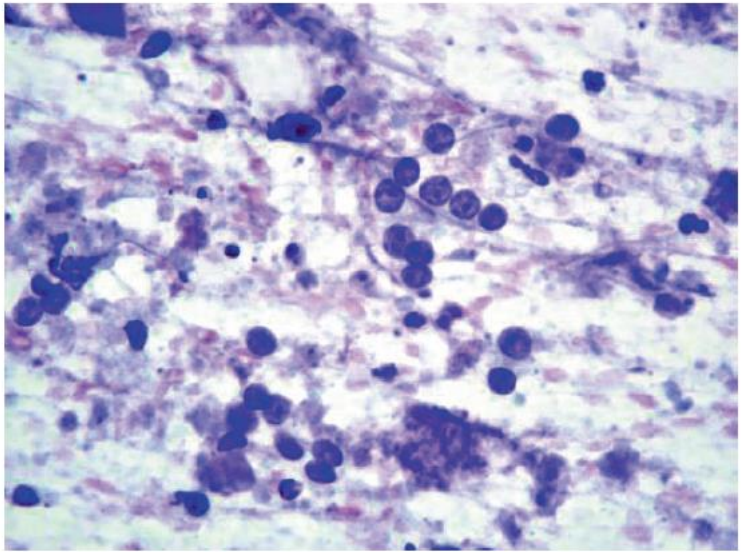

ANAPLASTIC THYROID CARCINOMA

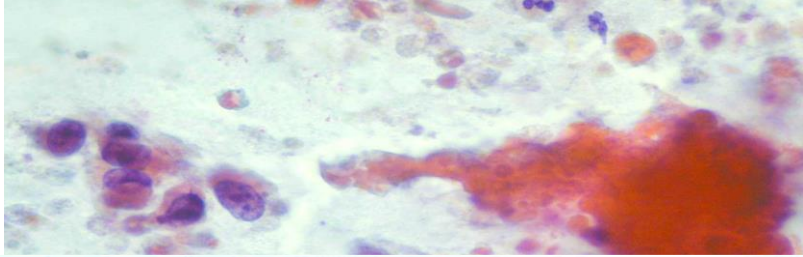

- Rapidly growing nodule in an elderly patient
- Variable cellularity as isolated and variably sized groups
- Striking cellular and nuclear pleomorphisms with prominent nucleoli
- Necrotic debris and hemorrhagic background with neutrophils (abscess-like)

Mitotic figures

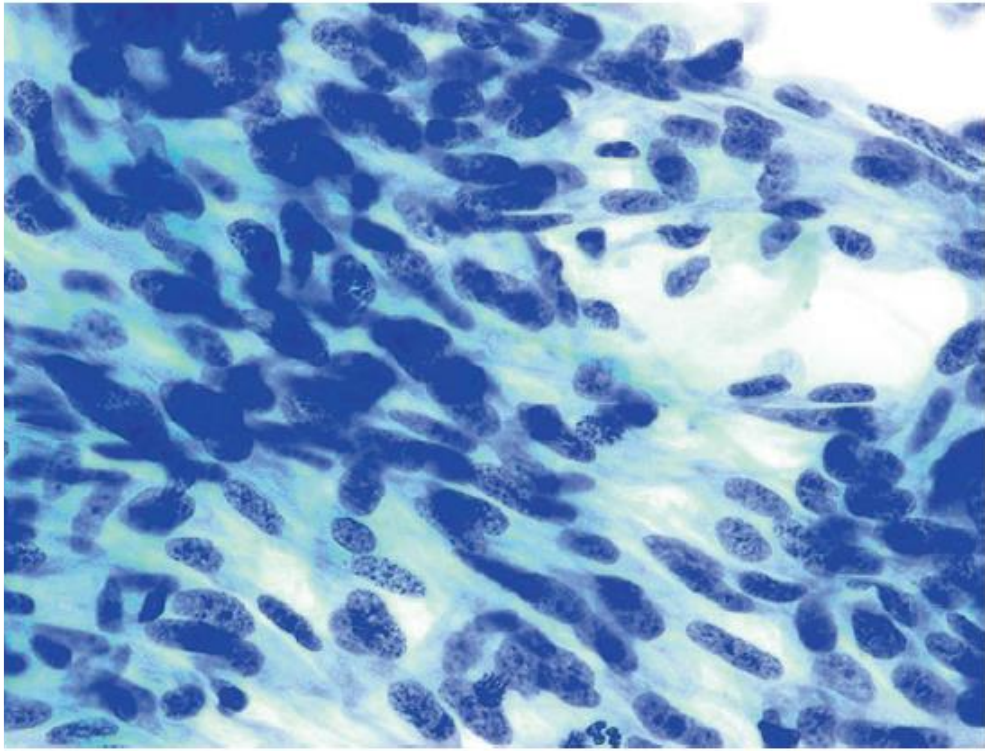

Metastatic lesion

- **Cellular smears with cell clusters or sheets**
- **Medium sized cellularity with variable amount of cytoplasm and/or mucin**
- **Round to oval nuclei, eccentrically located**
- **Finely granular and coarse chromatin**

Nucleoli may be prominent

→ ANCILLARY TECHNIQUES

Your diagnosis?

- **A) SM**
- **B) POSITIVE FOR MALIGNANCY-PTC**
- **C) MTC**
- **D) FOLLICULAR NEOPLASM WITH SPINDLE FEATURES AND FEW PLEOMORPHIC FINDINGS**

IMMUNOCYTOCHEMICAL RESULTS

Cell block slides-obtained from LBC stored material- were used for ICC:

Positivity

Thyroglobulin
TTF-1

Negativity

HBME-1
Galectin-3
Calcitonin
CEA
CD34
Vimentin

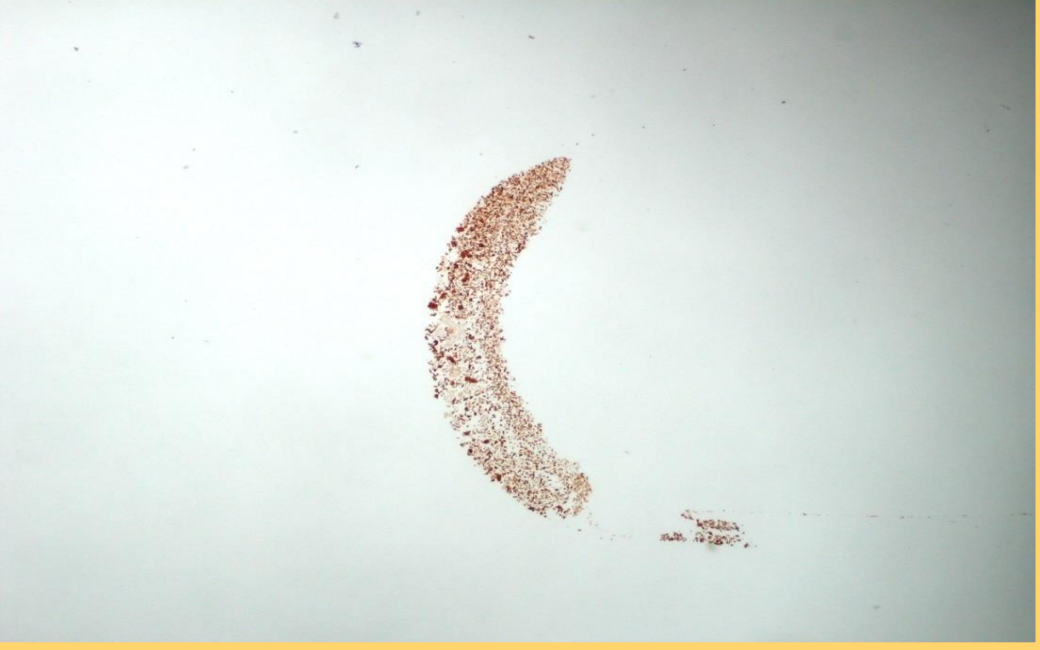

What i had in my hands

- **Morphology of follicular proliferation with spindle-elongated features and focal-mild nuclear irregularities**
- **ICC favoring a thyroid origin**
- ***BRAFV600E wt***

HOW SHOULD I CALL IT?

Follicular neoplasm (HBME-1 and Gal-3 negative)

OR

Papillary Thyroid carcinoma (morphology and IIC not in favor)

OR

Suspicious for malignancy (for the irregularities and don't care about HBME-1 and Gal-3)

FINAL CYTOLOGICAL DIAGNOSIS

Well differentiated thyroid proliferation with some spindle-elongated features and few mild nuclear pleomorphisms (follicular adenoma? HTT?mesenchimal lesion?)

HISTOLOGICAL RESULTS

- **Histology revealed a 3 cm capsulated nodule**
- **Histological features:**

  1)Trabecular structures

  2) polygonal-spindle cells with irregularities and some grooves but few nuclear pseudo-inclusions

  3) cylindrical –ovoid nuclei

  4) eosinophilic granular cytoplasm

The IIC resulted in:

POSITIVITY

Thyroglobulin

TTF-1

S100

MIB-1

NEGATIVITY

HBME-1

Galectin-3

Calcitonin/mCEA

β-Catenin

CK-19

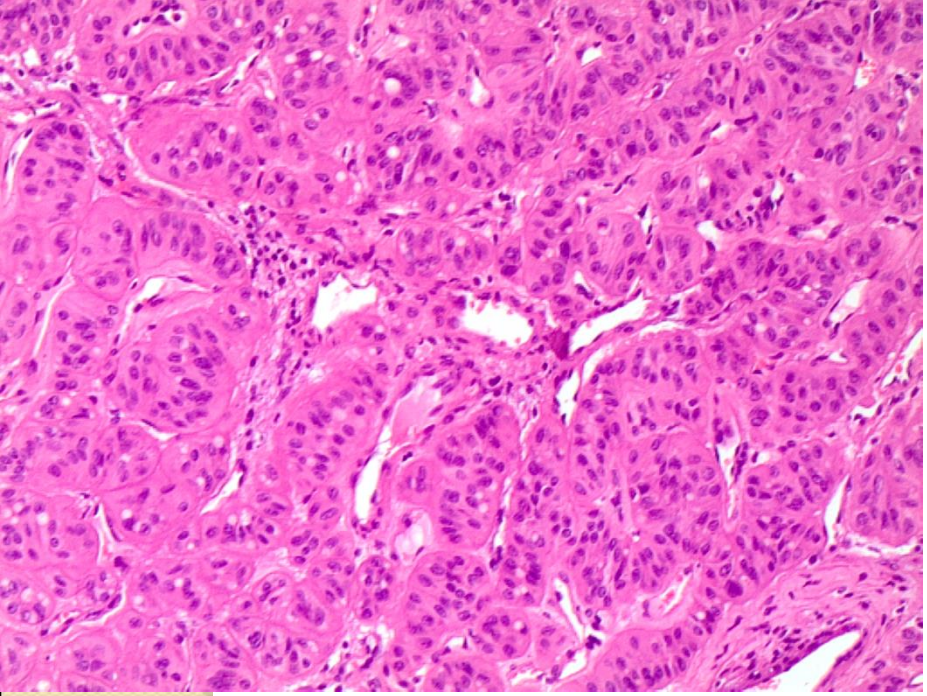

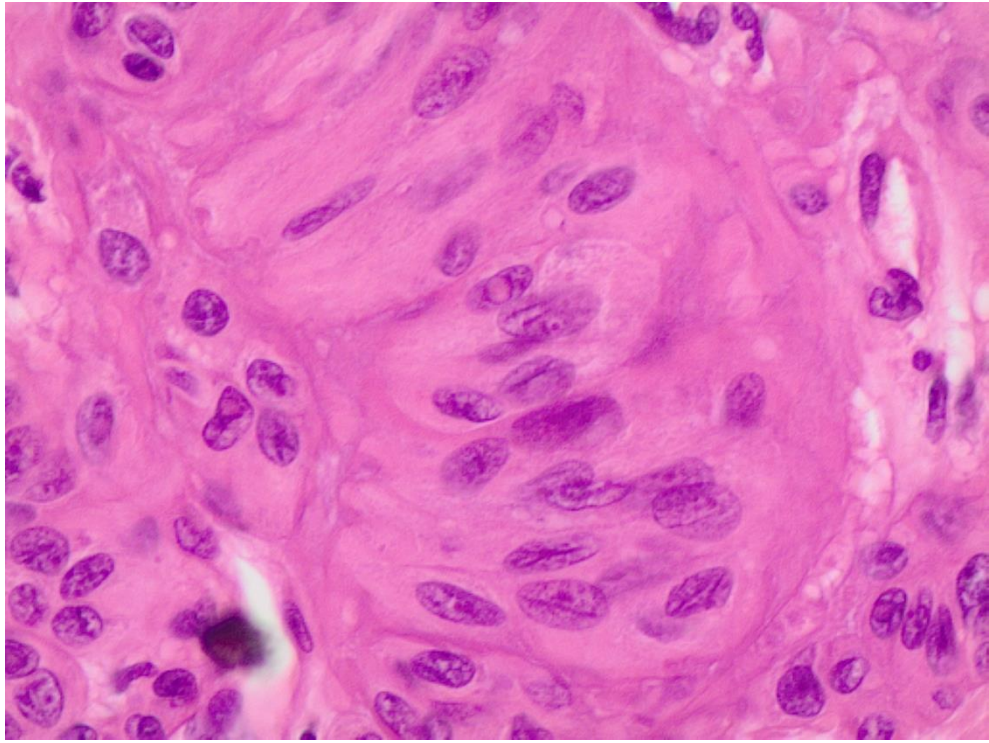

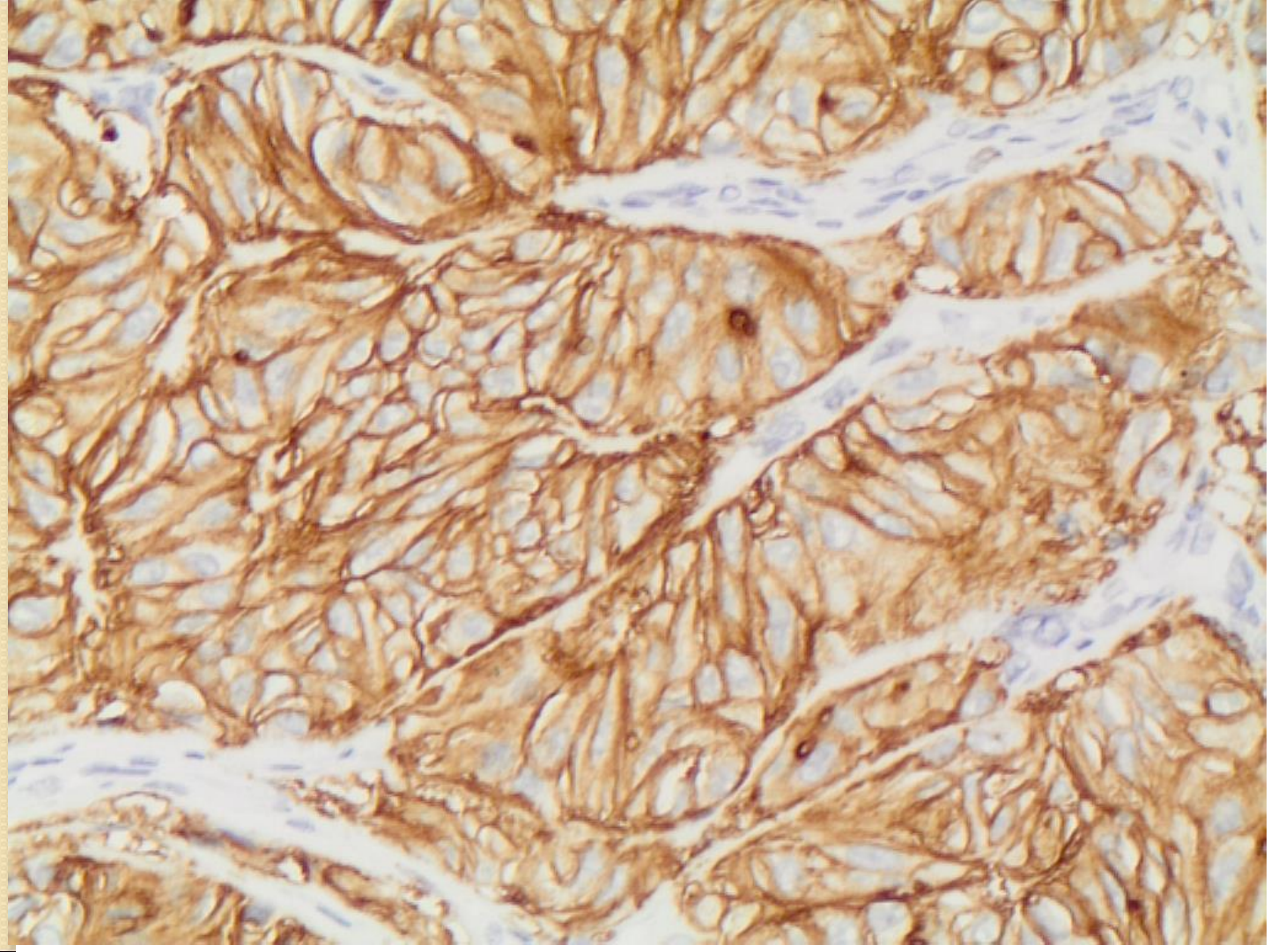

DIAGNOSIS?

Hyalinizing Trabecular Tumor

BALLY'S
WELCOME
TO Fabulous
LAS VEGAS
NEVADA

Paris
© CanStockPhoto.com - csp57728132



HTT

- First described in 1895 by Zipkin but introduced as a rare follicular-derived neoplasm in 1987 by Carney

Neoplastic capsulated lesion characterized by trabecular/alveolar pattern with intra-extracellular hyaline material

- Polygonal or elongated/spindle cells
- nuclear features are very similar to those of PTC

- 20-40% of HTTs show RET/PTC1 rearragement
- Difficult cytological recognition due to:

Sharing features with PTC

1)Its rarety

2)Morphological overlapping with PTC

3)Medullary carcinoma

HTT AND CYTOLOGY

A Large Series of Hyalinizing Trabecular Tumors: Cytomorphology and Ancillary Techniques on Fine le Aspiration

D[2]; Alessandra Cocomazzi, BD[1]; Sara Capodimonti, BD[1]; ı, MD[1]; Vincenzo Fiorentino, MD[1]; Luca Revelli, MD[2]; D[1]; Liron Pantanowitz, MD[3]; Luigi Maria Larocca, MD[1]; Diana Rossi, MD, PhD[1]

TABLE 2. Comparative Distribution of Hyalinizing Trabecular Tumor Cases According to Cytological Categories per Italian and Bethesda Reporting Systems

SIAPEC-IAP classification	TIR 2	TIR 3A	TIR3B	TIR4	TIR5
TBSRTC	II (benign)	III (AUS/FLUS)	IV (FN/SFN)	V (SFM)	VI (malignant)
No. of cases (%)	1 (5.5)	4 (22.2)	6 (33.3)	5 (28)	2 (11)

TABLE 3. Cytomorphological Features of Hyalinizing Trabecular Tumor

	Diagnostic Category				
Feature	Benign	AUS/FLUS	FN/SFN	SFM	Malignant
Hyaline material	Absent	Absent	Absent	Absent	Absent
Nuclear pseudoinclusions	Absent	Absent	Absent	Absent	Focal
Nuclear grooves	Absent	Absent	Absent	Few cells	Few cells
Mild nuclear atypia	Absent	Focal	Absent/focal	Focal	Some cells
Severe nuclear atypia	Absent	Absent	Absent	Focal	Some cells
Colloid	Focally present	Absent	Absent	Absent	Absent

AUS/FLUS, atypia of undetermined significance/follicular lesion of undetermined significance; FN/SFN, follicular neoplasm/suspicious for follicular neoplasm; SFM, suspicious for malignancy.

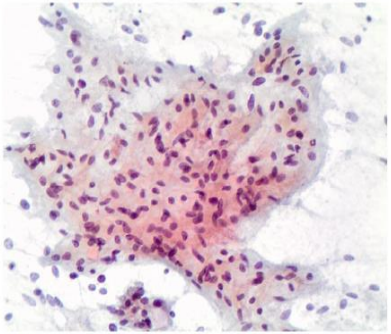

Table 2. Morphologic

TABLE 4. Immunocytochemistry Results for Hyalinizing Trabecular Tumor Cases

	Benign	AUS/FLUS	FN/SFN	SFM	Malignant
H+/G+	0	0	0	0	0
H–/G–	1	3	6	4	2
H+/G–	0	0	0	1	0
H–/G+	0	1	0	0	0

Abbreviations: AUS/FLUS, atypia of undetermined significance/follicular lesion of undetermined significance; FN/SFN, follicular neoplasm/suspicious for follicular neoplasm; G, galectin-3; H, HBME-1; SFM, suspicious for malignancy; +, positive; –, negative.

Values represent the numbers of positive cases. All cases had weak to slightly moderate positivity.

MIB-1*	+	-	-	-
cytokeratin-19	-	+	-	+/-
Galectin-3	-/+	+	+	+/-

THYROID
Volume 29, Number 2, 2019
© Mary Ann Liebert, Inc.
DOI: 10.1089/thy.2018.0791

SPECIAL ARTICLE

GLIS Rearrangement is a Genomic Hallmark of Hyalinizing Trabecular Tumor of the Thyroid Gland

Marina N. Nikiforova,[1] Alyaksandr V. Nikitski,[1] Federica Panebianco,[1] Cihan Kaya,[1] Linwah Yip,[2] Michelle Williams,[3] Simion I. Chiosea,[1] Raja R. Seethala,[1] Somak Roy,[1] Vincenzo Condello,[1] Lucas Santana-Santos,[1] Abigail I. Wald,[1] Sally E. Carty,[2] Robert L. Ferris,[4] Adel K. El-Naggar,[3] and Yuri E. Nikiforov[1]

TABLE 1. CHARACTERISTICS OF TUMORS INITIALLY DIAGNOSED AS HTT

Study

TABLE 2. PREVALENCE OF *PAX8–GLIS3* AND *PAX8–GLIS1* FUSIONS IN THE CURRENT STUDY AND TCGA COHORT

		PTC			
Fusion type	*HTT, current study (n=14)*	*TCGA study*[a] *(n=484)*	*Current study, unselected PTC (n=111)*	*Current study, aggressive PTC (n=109)*	*Total*
PAX8–GLIS3	13/14 (93%)	0/484	0/111	0/109	0/704 (0.0%)
PAX8–GLIS1	1/14 (7%)	0/484	1[b]/111	0/109	1/704 (0.1%)

[a]As reported by TCGA Research Network (56).
[b]The same case was reported as *PAX8/GLIS1* positive in TCGA PanCancer Atlas study (see www.cbioportal.org/).
TCGA, The Cancer Genome Atlas.

* Initially diagnosed as HTT, reclassified after blind pathology review.

TAKE HOME MESSAGE

PTC and MTC are the main morphological pitfalls for HTT on FNAC

The ICC and *BRAF* analysis can not achieve a 100% diagnostic accuracy but they might be performed on FNA supporting a more accurate preoperative diagnosis

Combine morphology and ancillary techniques with clinical and radiological findings

The detection of *GLIS* rearrangements, particularly *PAX8-GLIS3* is highly prevalent in HTT but not in PTC

. Due to unique genetic mechanisms and an indolent behavior, it is proposed to rename this tumor as "*GLIS*-rearranged hyalinizing trabecular adenoma."

tant

THANK YOU

FOR YOUR ATTENTION