Immunohistochemical Markers Which May Serve as Surrogates for Underlying Molecular Genetic Events

Andrew L. Folpe, MD
Mayo Clinic, Rochester MN
folpe.andrew@mayo.edu

©2016 MFMER

The Dawn of Diagnostic Immunohistochemistry

Immunochemical Identification of Intermediate-Sized Filaments in Human Neoplastic Cells

A Diagnostic Aid for the Surgical Pathologist

GIULIO GABBIANI, MD, PhD, YUSUF KAPANCI, MD, PHILIPPE BARAZZONE, MD, and WERNER W. FRANKE, PhD

From the Department of Pathology, University of Geneva, Geneva, Switzerland, and the Department of Membrane Biology and Biochemistry, Institute for Cell and Tumor Biology, German Cancer Research Center, Heidelberg, Federal Republic of Germany

Forty-three tumors were investigated by means of immunofluorescence with the use of antibodies against the following different classes of intermediate-sized (10 nm) filament proteins: 1) cytokeratins, 2) vimentin, and 3) desmin. In general, the immunologic features of tumor-cell intermediate filaments are those present in their tissue of origin. It can be seen, therefore, that, during neoplastic transformation, there are no major changes in the synthesis of the type of intermediate filament proteins when compared to normal tissues. Immunologic identification of these proteins furnishes the surgical pathologist with a quick and clear-cut way to differentiate tumors of mesenchymal origin from epithelial neoplasms, and in particular to distinguish between malignant lymphomas and lymph node metastases of undifferentiated carcinomas. (Am J Pathol, 1981, 104:206–216)

©2016 MFMER

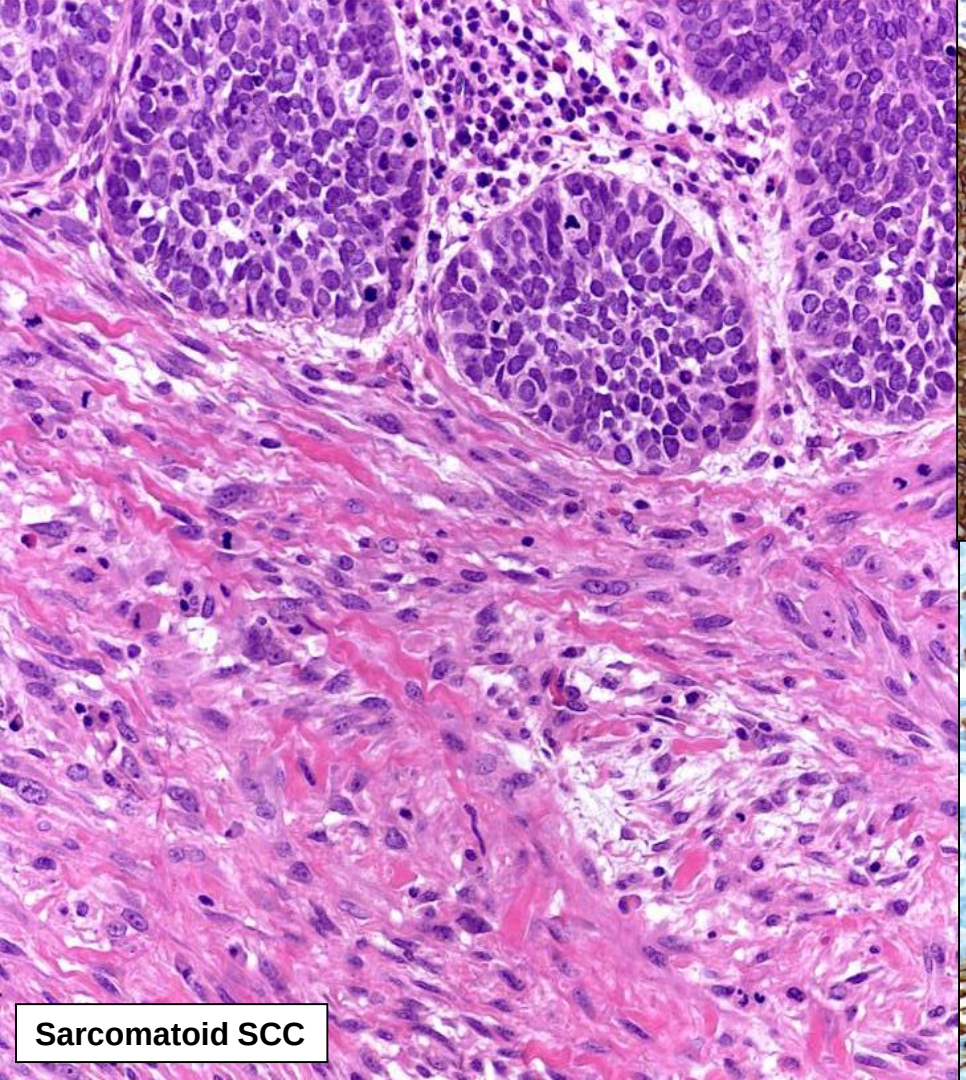
Sarcomatoid SCC

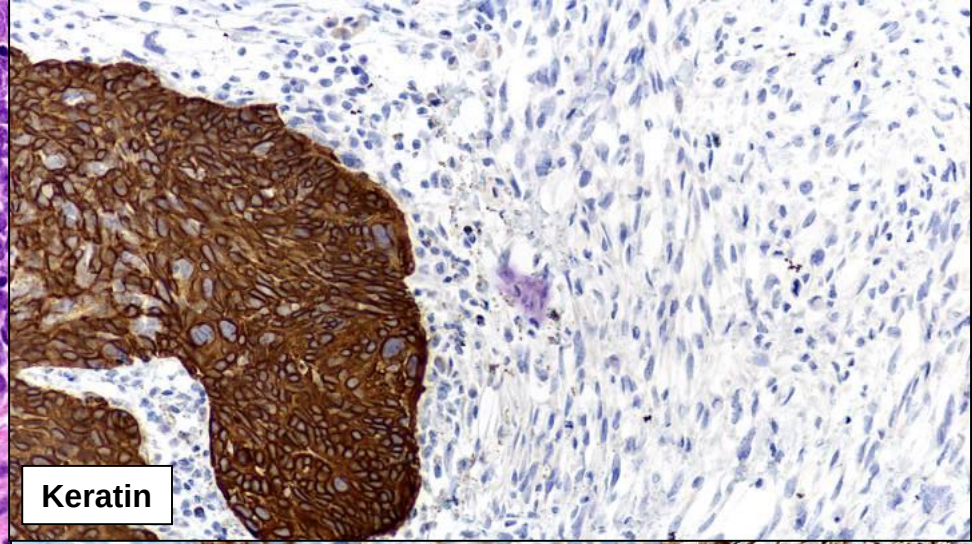
Keratin

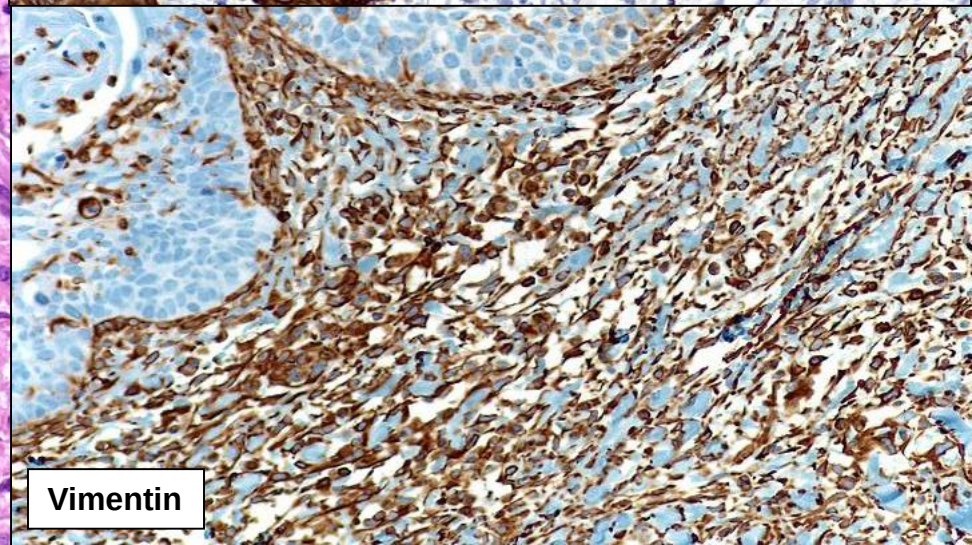
Vimentin

Lineage-Associated Cytoplasmic and Membrane Markers

- Epithelial
  - EMA, CEA, BerEp4, others
- Nerve sheath
  - S100 protein, CD57, others
- Endothelial
  - Von Willebrand factor, CD31, CD34
- Melanocytic
  - HMB45, Melan-A, others
- Muscle
  - Actins, calponin, others
- Neuroectodermal
  - CD99, CD56, others
- Hematolymphoid
- Other lineages

©2016 MFMER

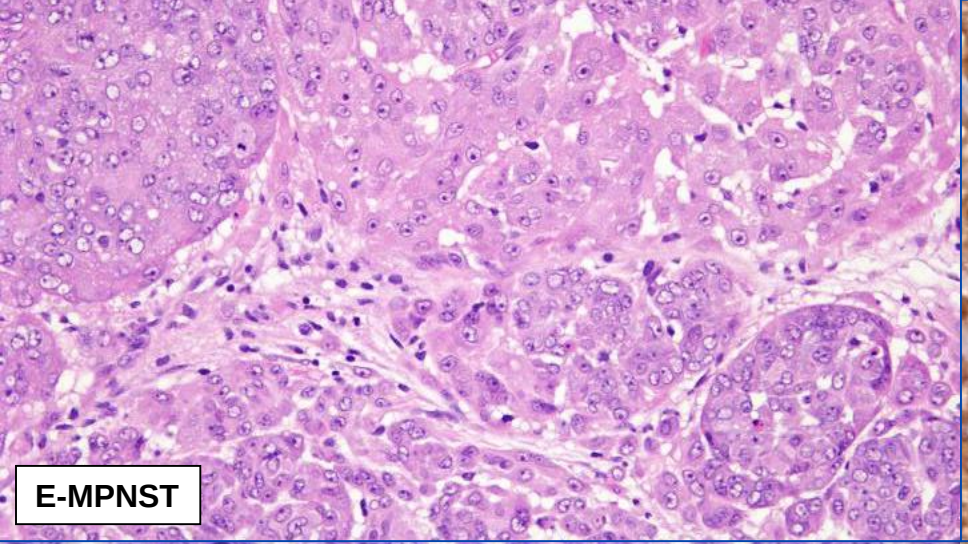
E-MPNST

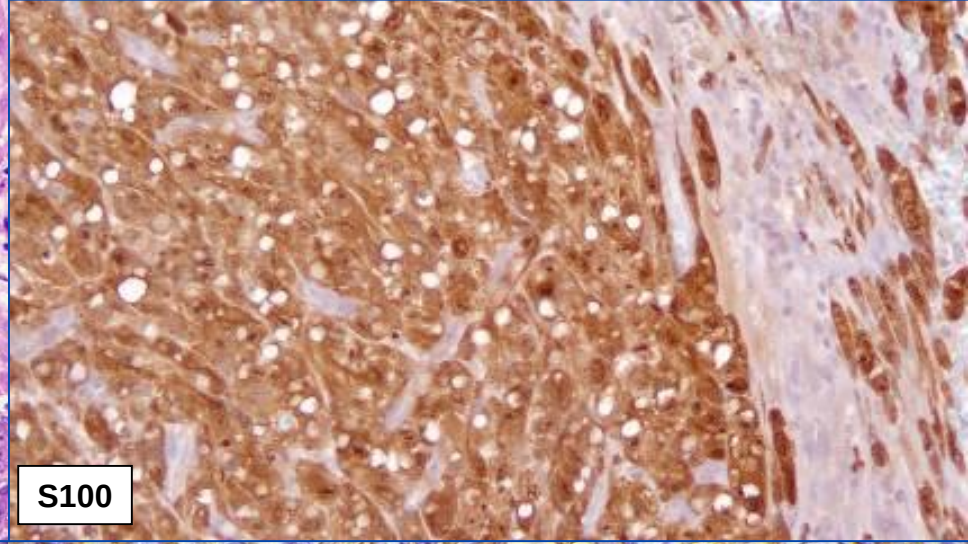
S100

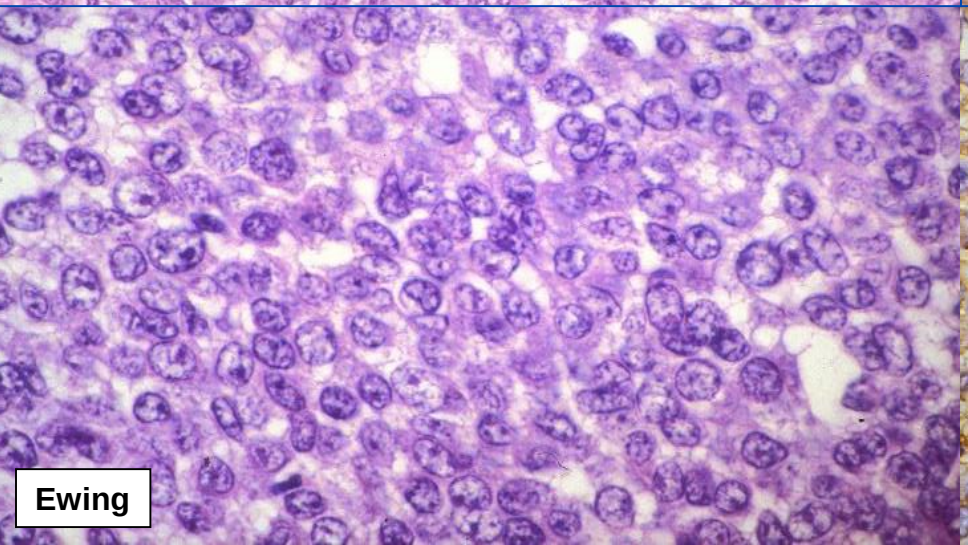
Ewing

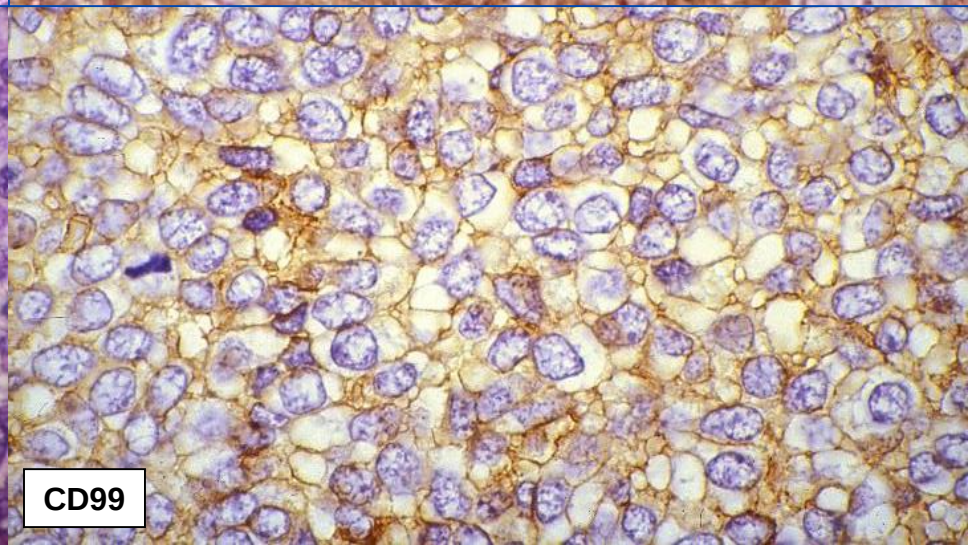
CD99

Lineage-associated Transcription Factors

- TTF1
- CDX2
- Myogenin and MyoD1
- WT1
- FLI1 and ERG
- Others

©2016 MFMER

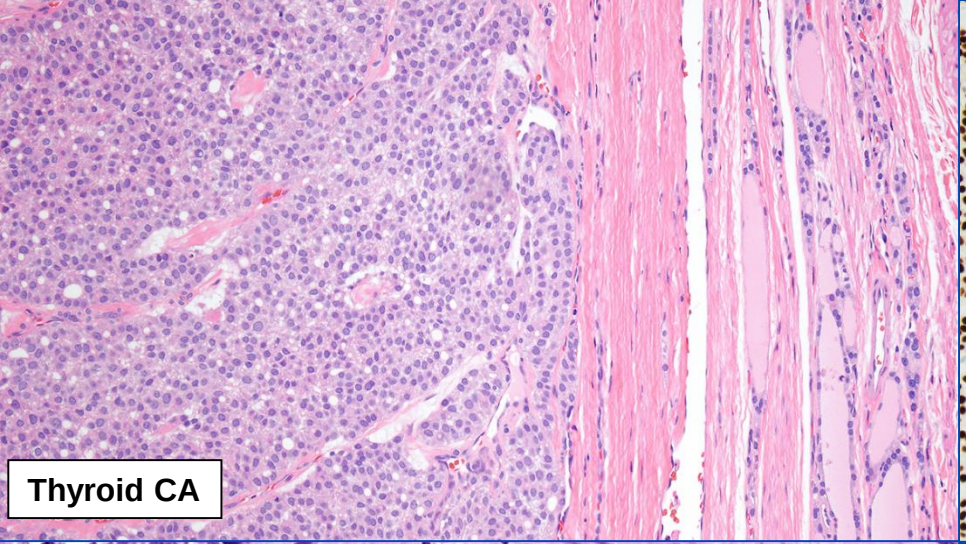
Thyroid CA

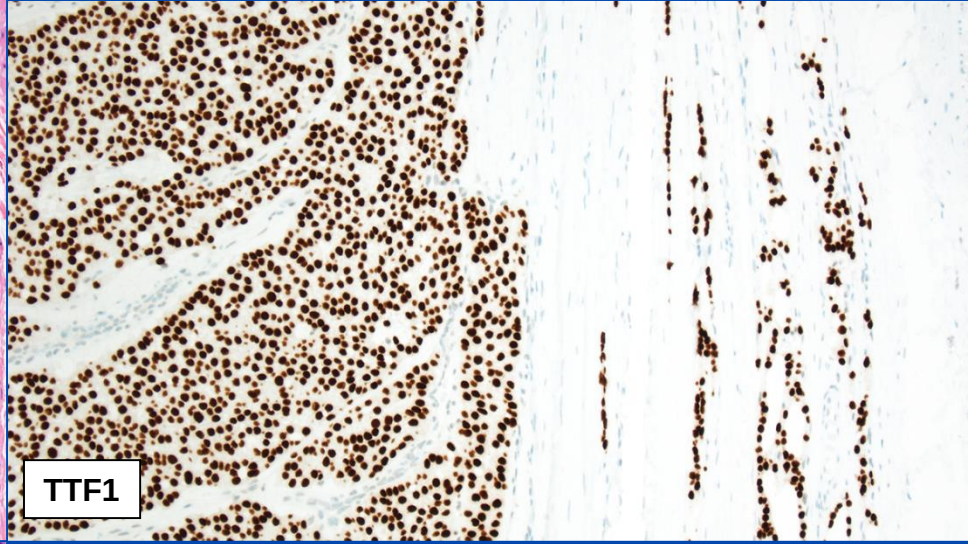
TTF1

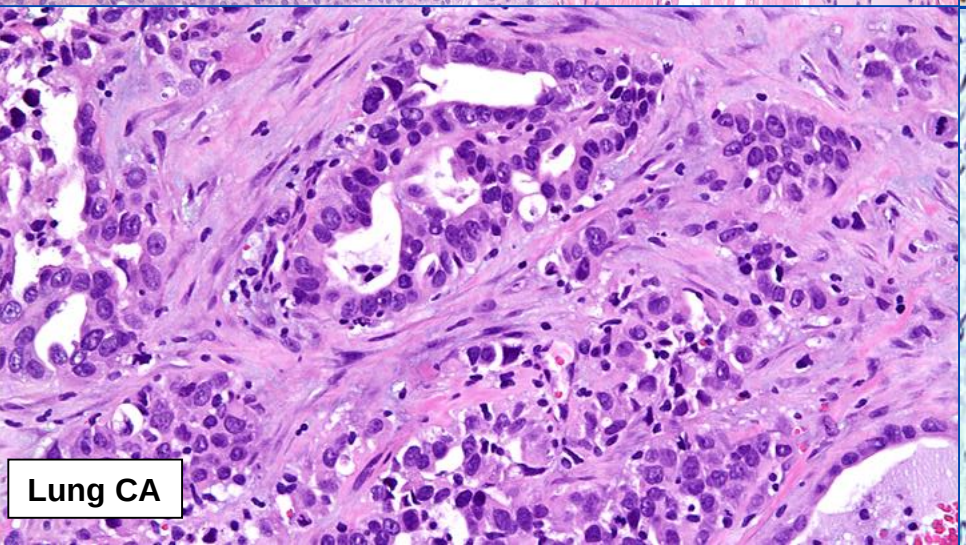
Lung CA

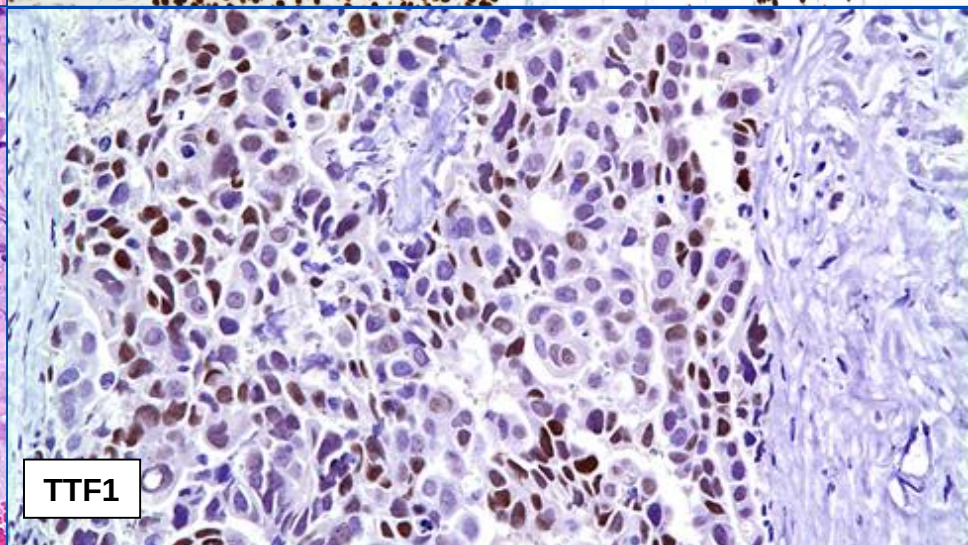
TTF1

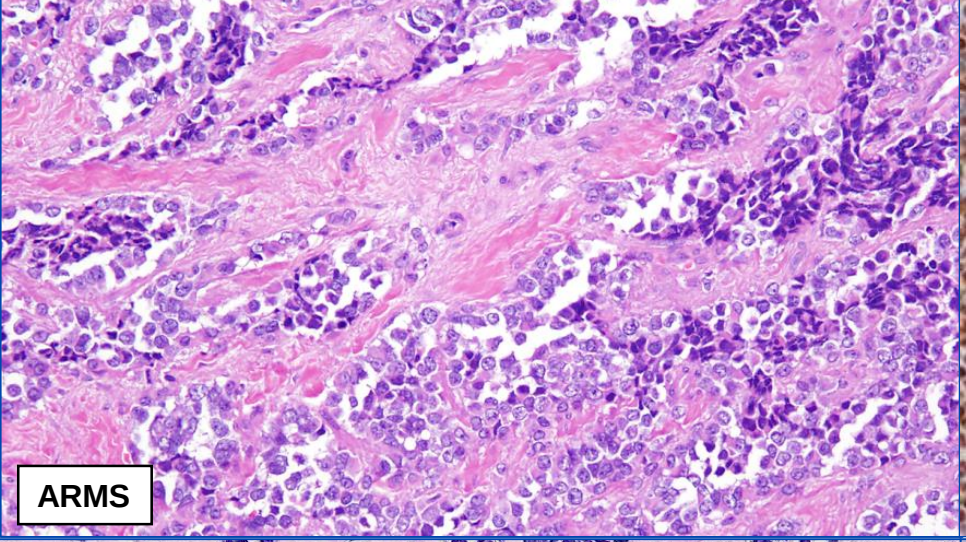
ARMS

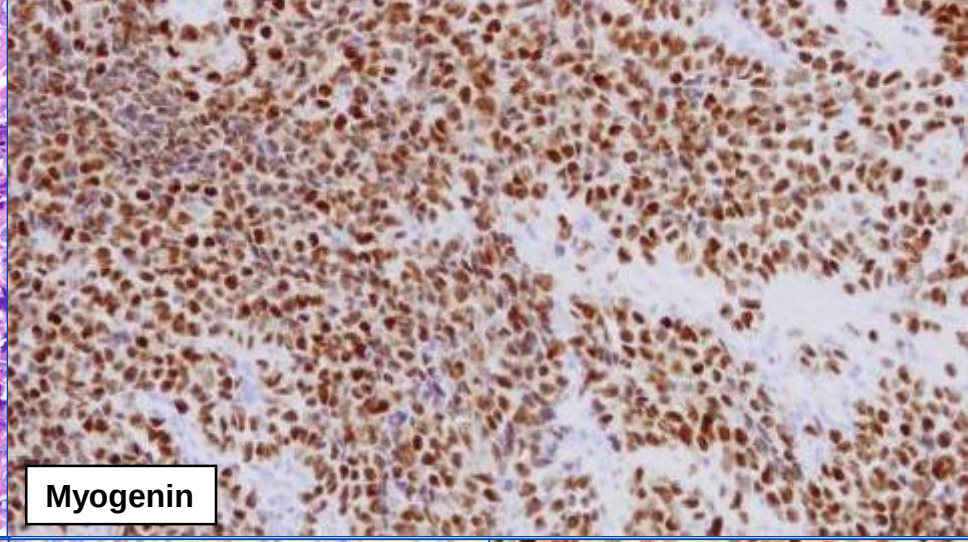
Myogenin

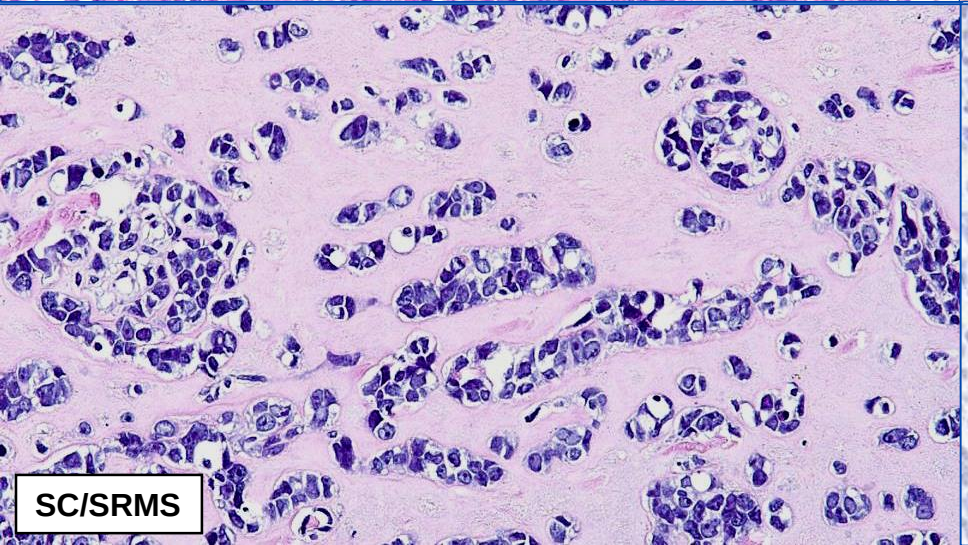
SC/SRMS

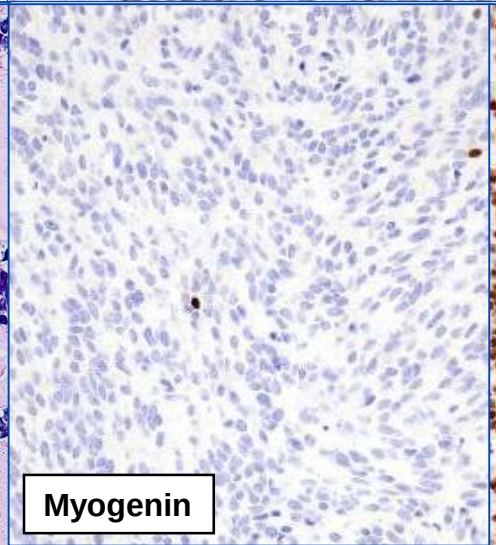
Myogenin

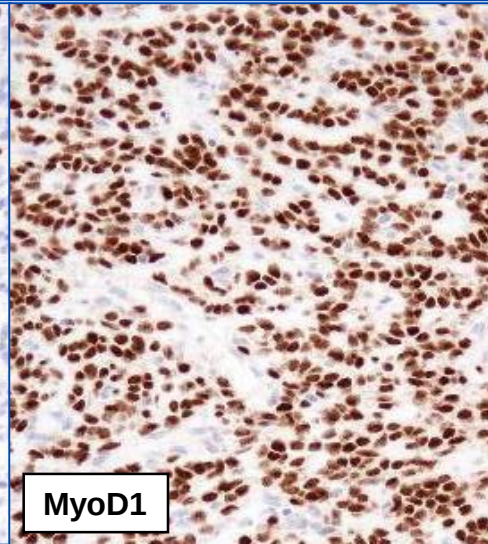
MyoD1

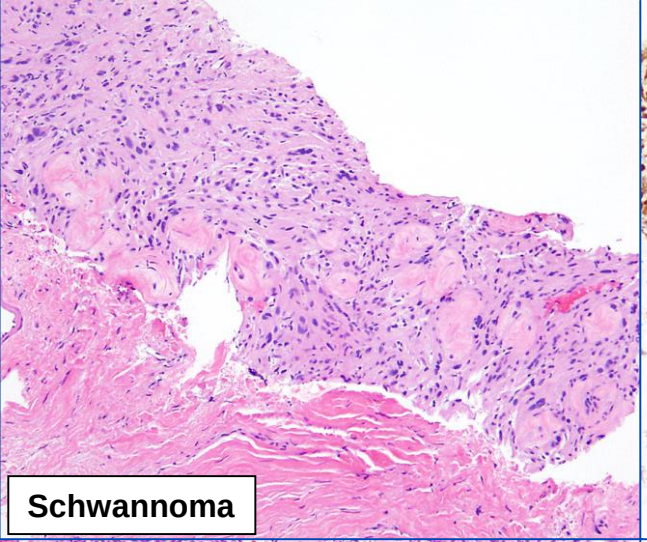
Schwannoma

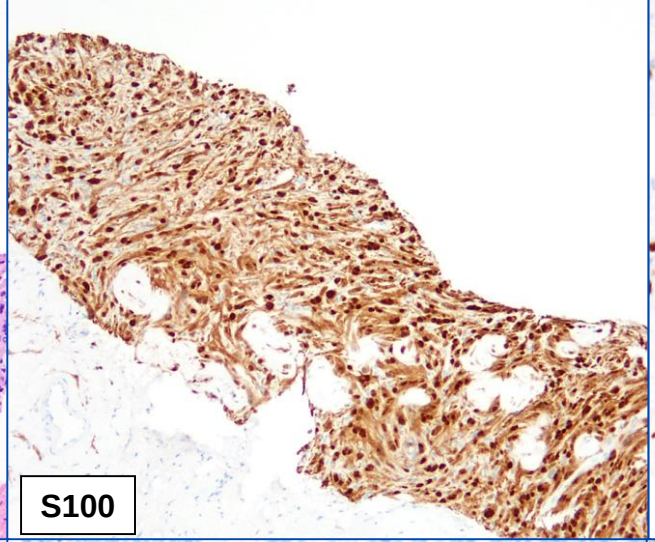
S100

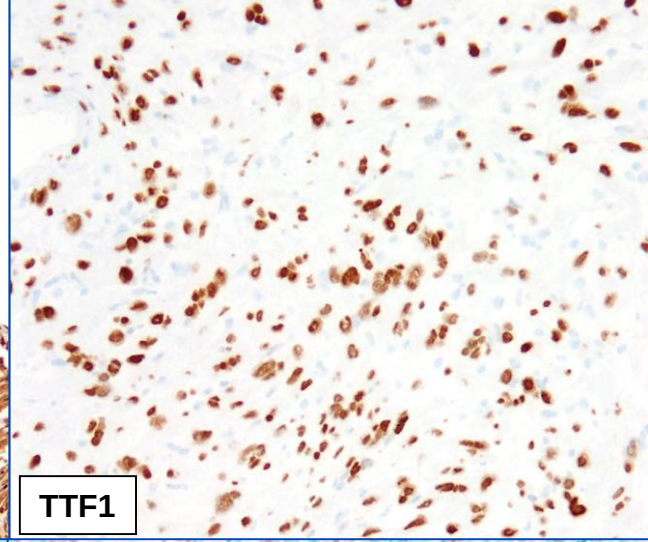
TTF1

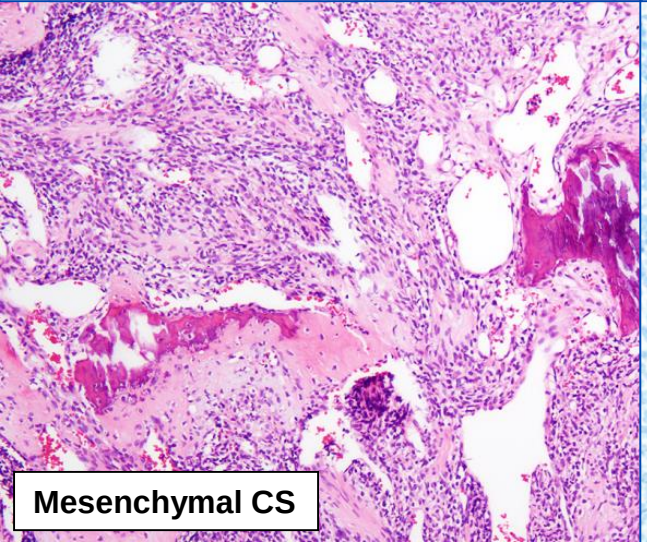
Mesenchymal CS

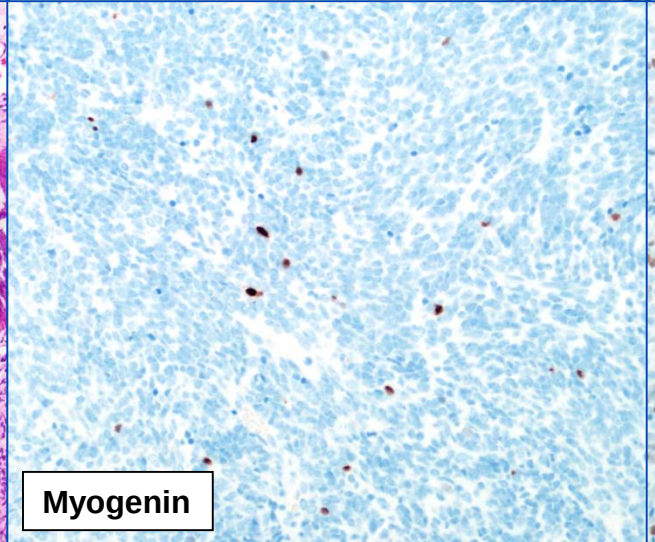
Myogenin

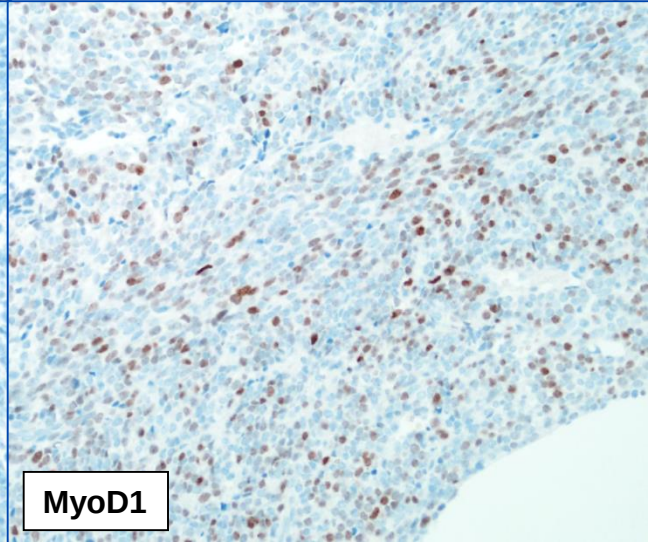
MyoD1

Surrogate IHC Markers of Underlying Genetic Events

- WT1
- FLI1
- ERG
- CAMTA1
- FOSB
- Beta-catenin
- MUC4
- PRKAR1A
- BCOR
- ETV4
- TRK
- TLE1
- TFE3
- *SMARC family*
- *MDM2/CDK4*
- *STAT6*
- *SATB2*
- *KIT*
- *Others*

©2016 MFMER

WT1

- Wilms' tumor-associated tumor suppressor gene, located on 11p13
- Expressed by mesothelium and ovarian surface epithelium
- Excellent marker of benign and epithelioid mesothelial tumors; less often positive in sarcomatoid mesothelioma
- Serous carcinoma

- Desmoplastic small round cell tumors
  - t(11;22)(p13;q24) (*EWSR1-WT1)*
- Identification of DSRCT with IHC requires *C-terminus* WT1 antibodies
- Very rare cases positive with N-terminus antibodies
- *CIC*-rearranged sarcomas routinely WT1-positive (95%)
- Ewing sarcoma and *BCOR*-rearranged sarcomas are WT1-negative

©2016 MFMER

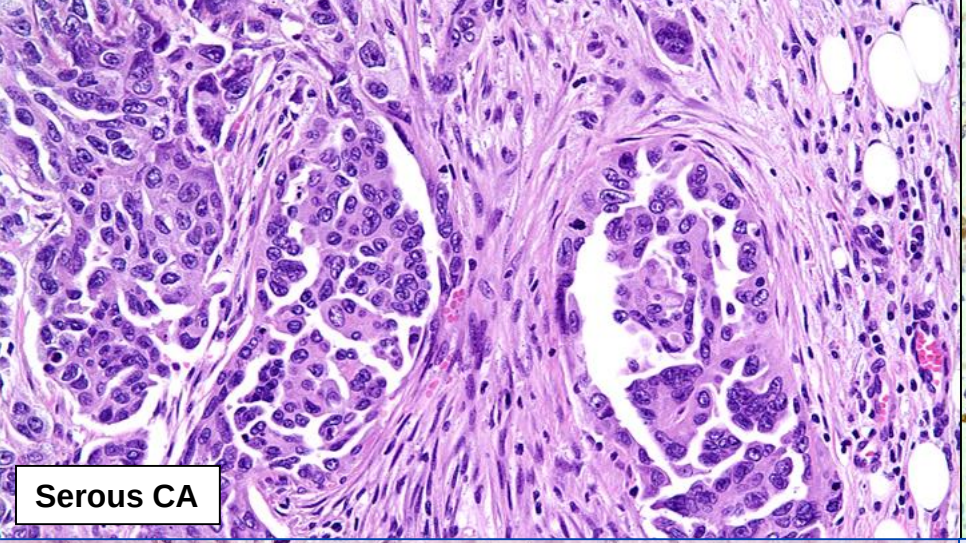
Serous CA

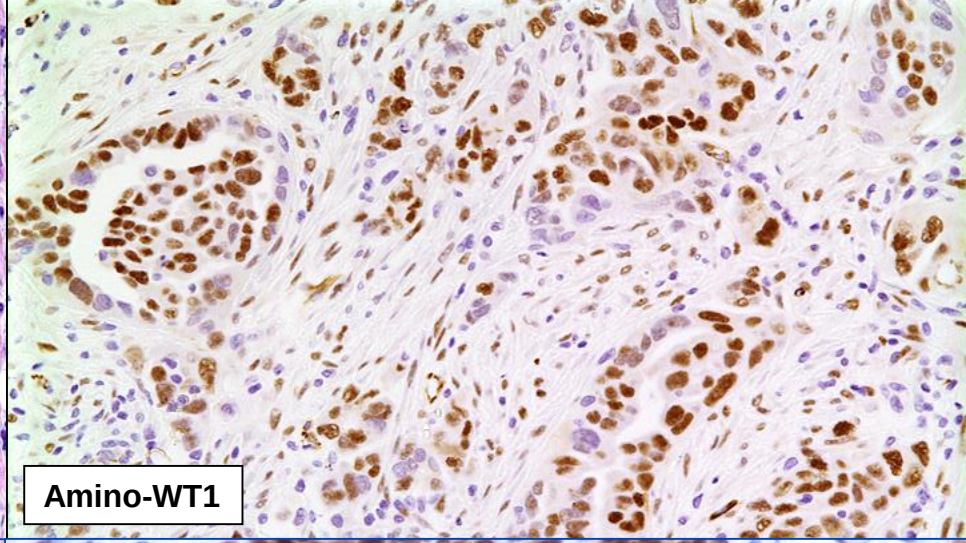
Amino-WT1

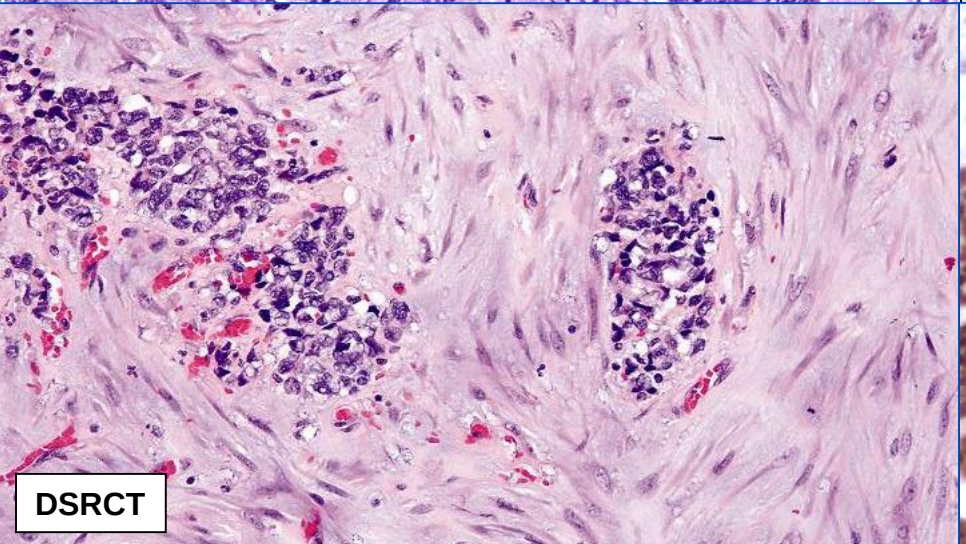
DSRCT

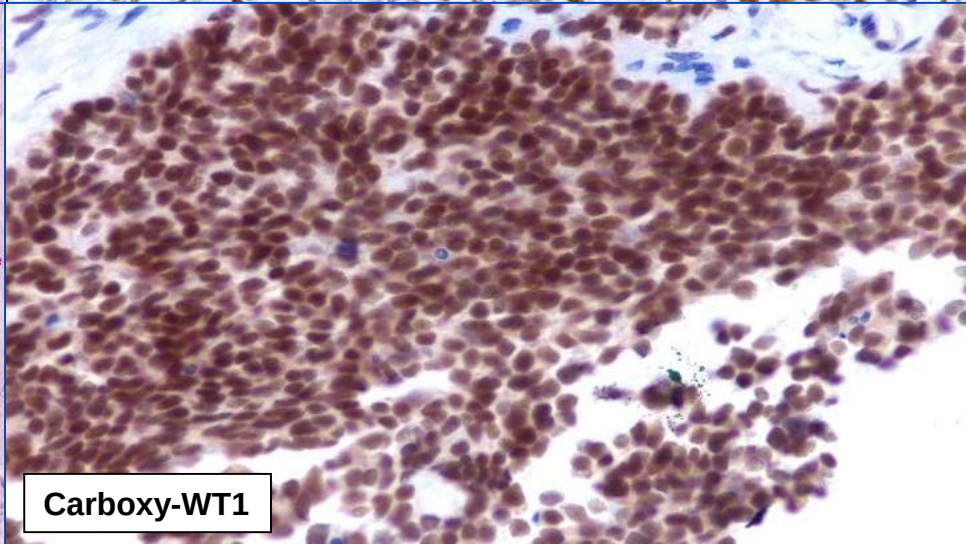
Carboxy-WT1

FLI1 and ERG

- Ewing sarcoma : *EWSR1-FLI1*(90%) and *EWSR1-ERG* (4%)
- Polyclonal and monoclonal antibodies to FLI1 positive in 70–90% of ES, most often reflecting the presence of the EWSR1-FLI1 fusion protein
- FLI-1 also positive in some cases with *EWSR1-ERG* fusions
- ERG antibodies are more specific for *ERG*-rearranged ES
- Best currently available *nuclear* markers of endothelial differentiation
- Both FLI1 and ERG positive in >95% of endothelial neoplasms of all types
- Conflicting data on FLI-1 and ERG in epithelioid sarcomas
- N-terminus ERG antibodies positive in some epithelioid sarcomas
- Some carcinomas and hematolymphoid tumors express FLI1 and/or ERG
- ERG expression in *EWSR1-SMAD3* tumors

©2016 MFMER

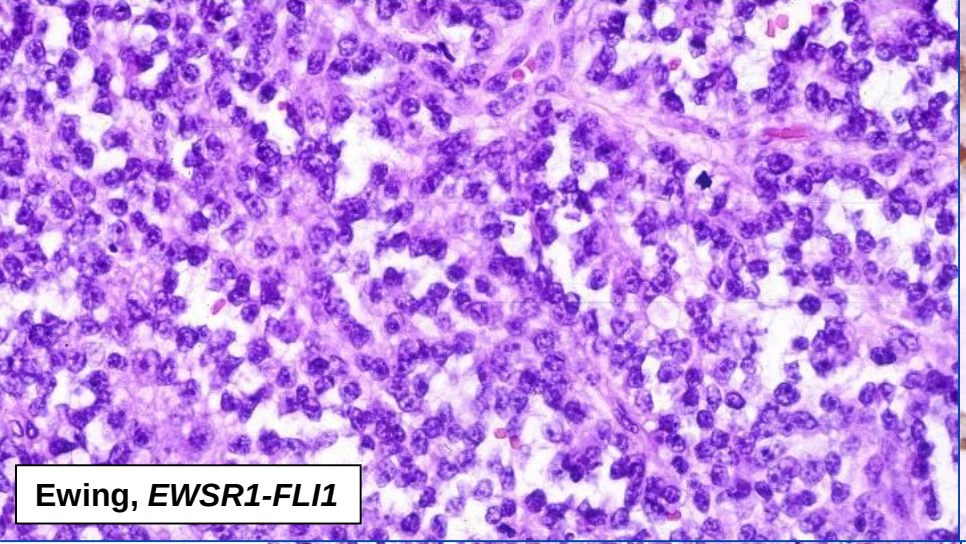
Ewing, *EWSR1-FLI1*

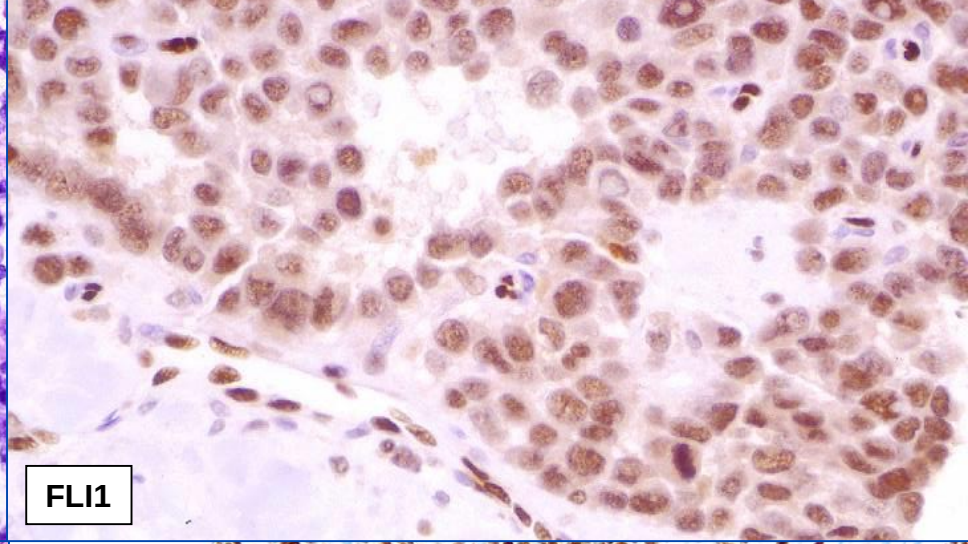
FLI1

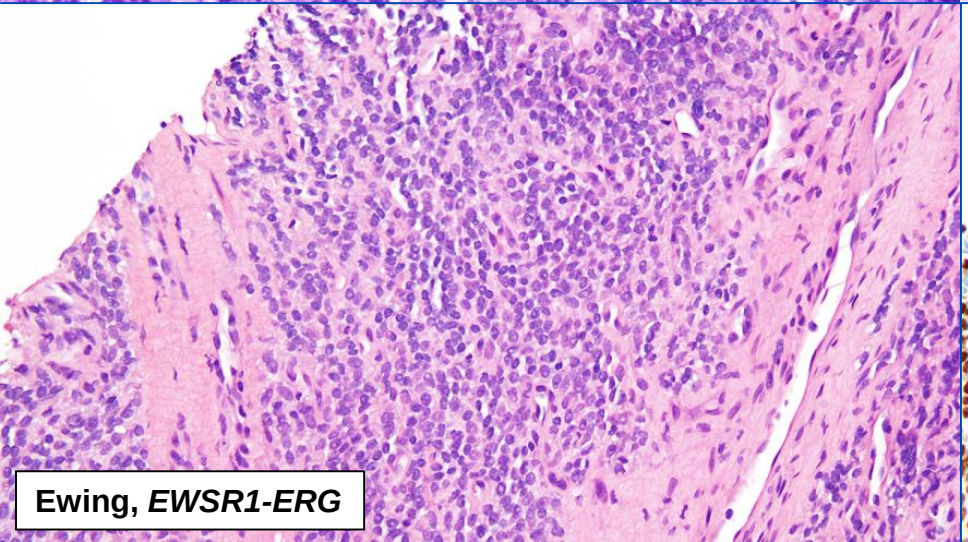
Ewing, *EWSR1-ERG*

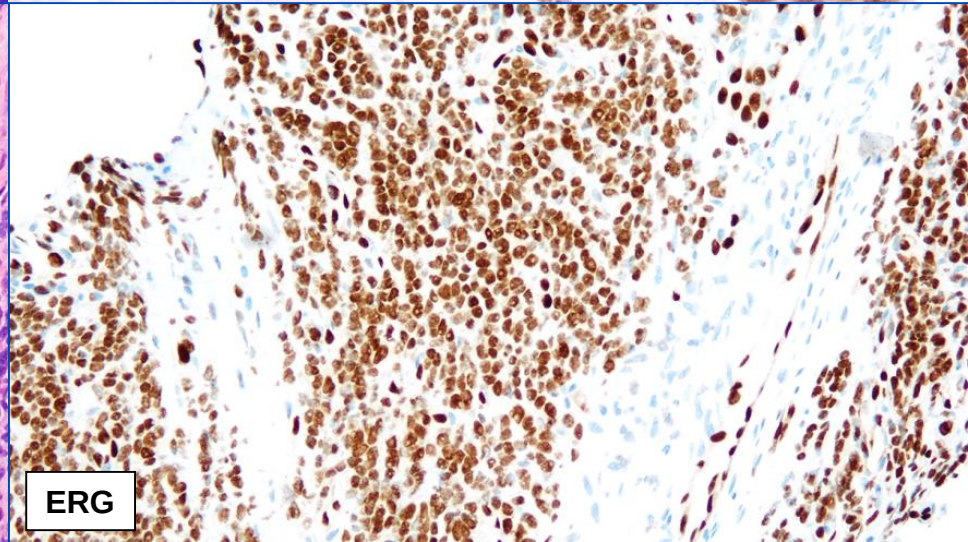
ERG

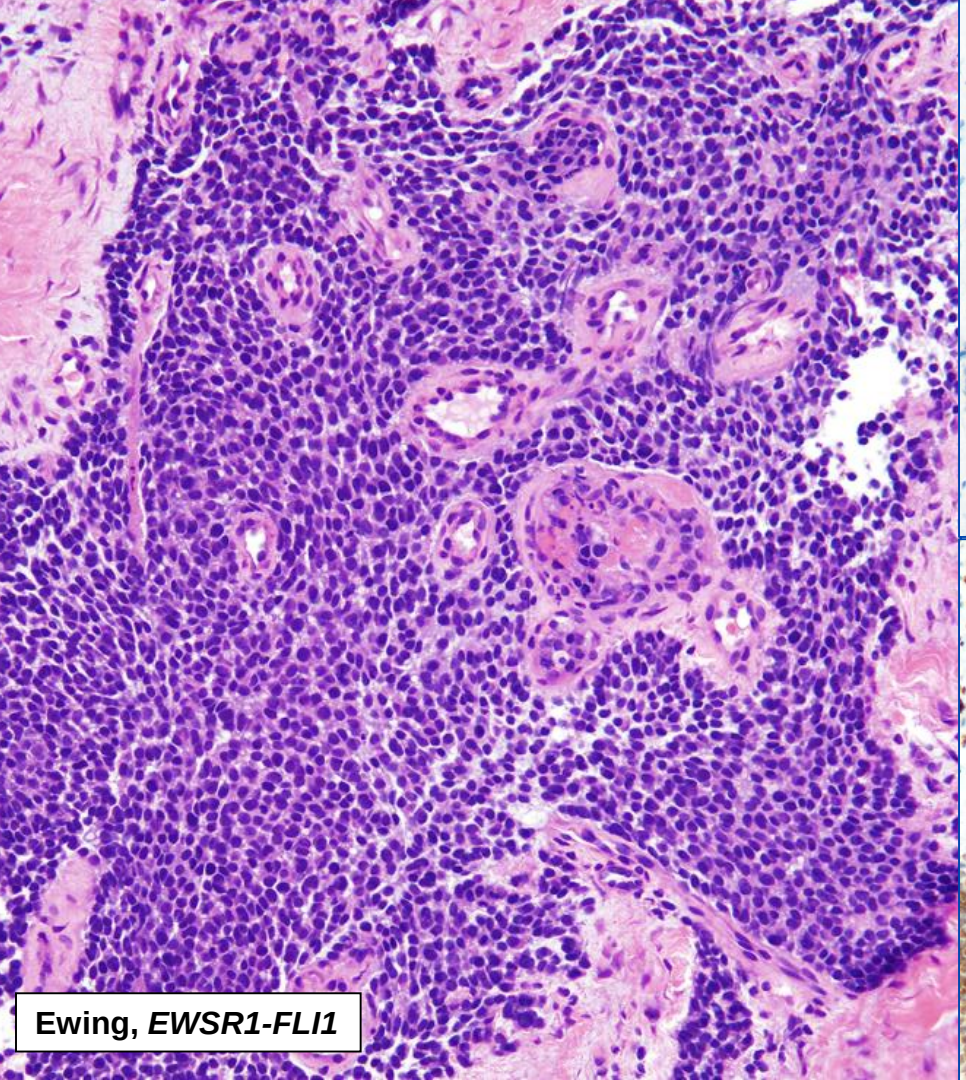
Ewing, *EWSR1-FLI1*

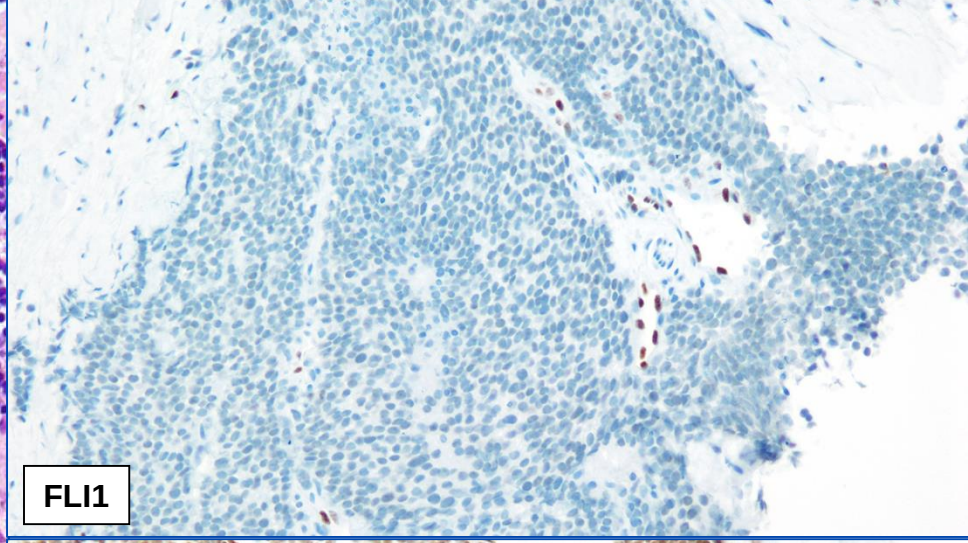
FLI1

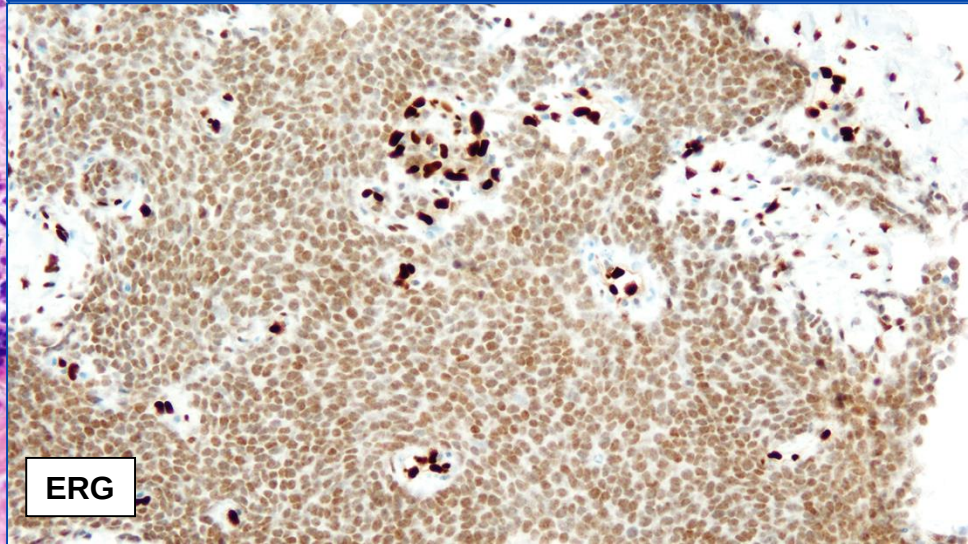
ERG

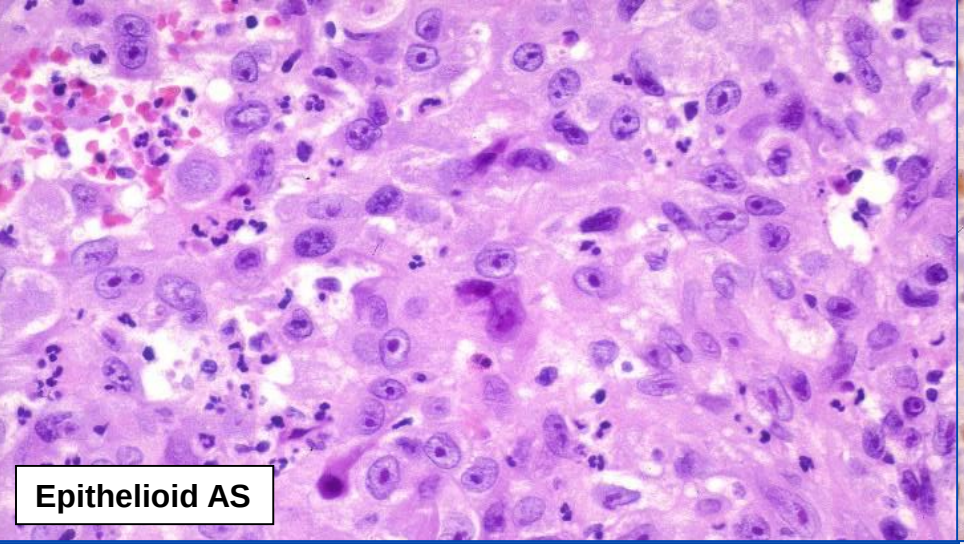
Epithelioid AS

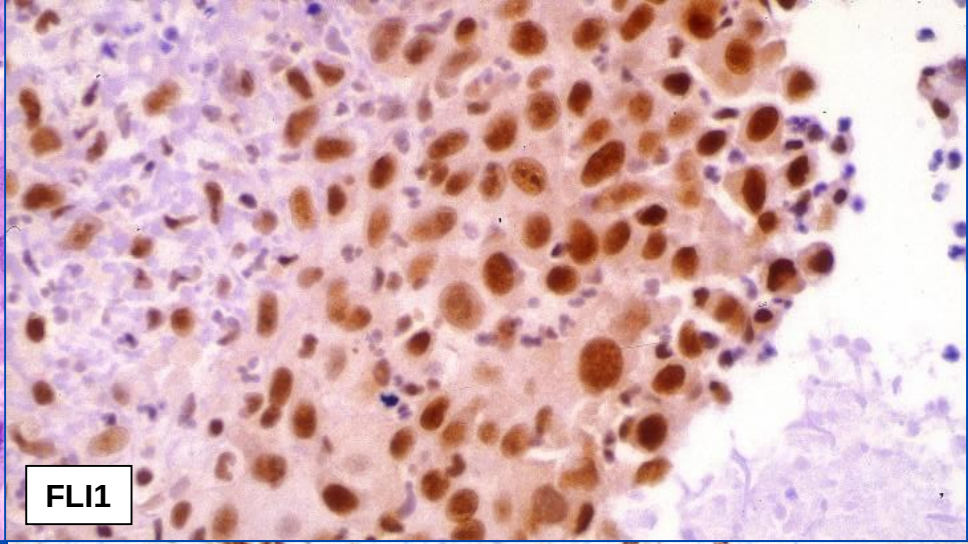
FLI1

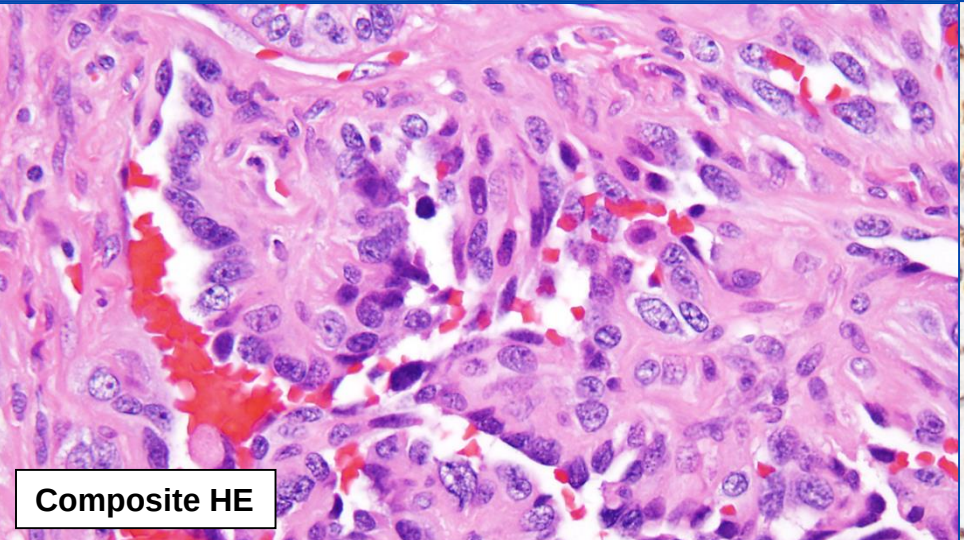
Composite HE

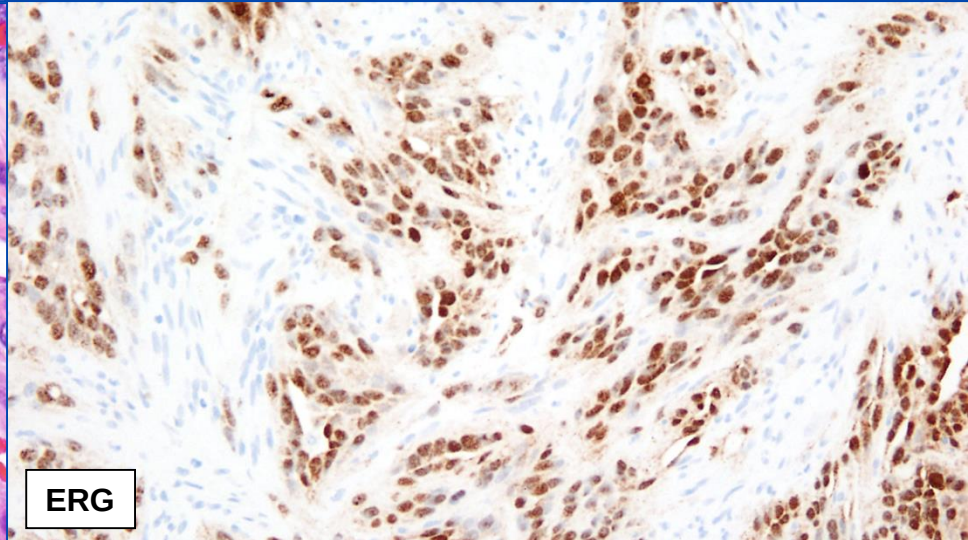
ERG

EWSR1-SMAD3 Fibroblastic Tumor

- Low-grade neoplasm with locally recurring potential
- Subcutis of hands and feet, most often in women
- Fusion of exon 7 of *EWSR1* with exon 5 of *SMAD3*
- Circumscribed but infiltrative into subcutaneous fat
- Acellular/ hyalinized central zone surrounded by intersecting cellular fascicles of bland fibroblastic spindle cells
- Dystrophic calcification
- Diffuse ERG expression

©2016 MFMER

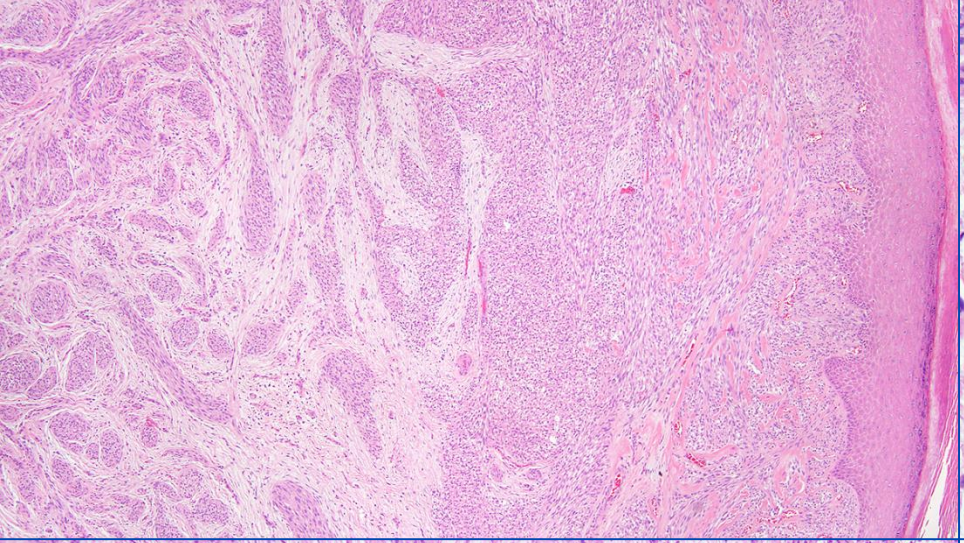

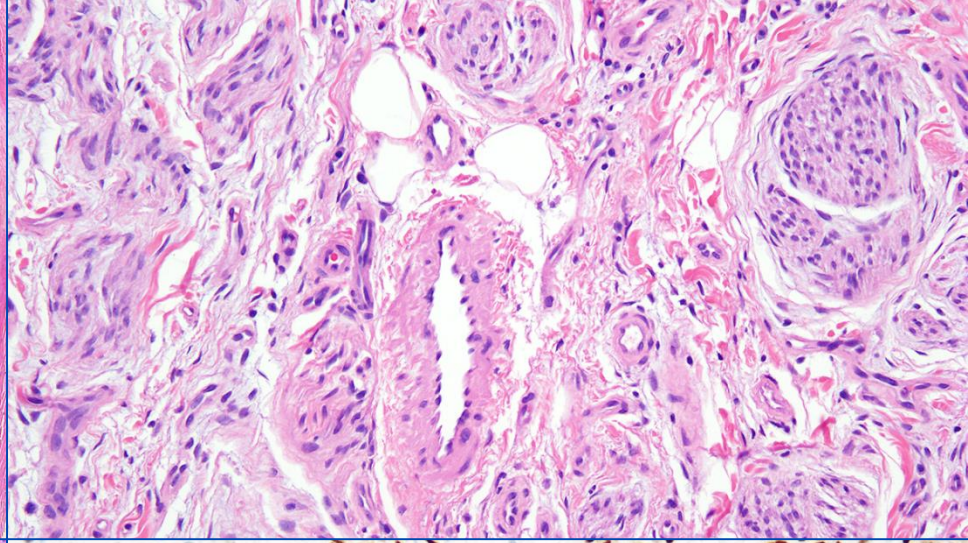

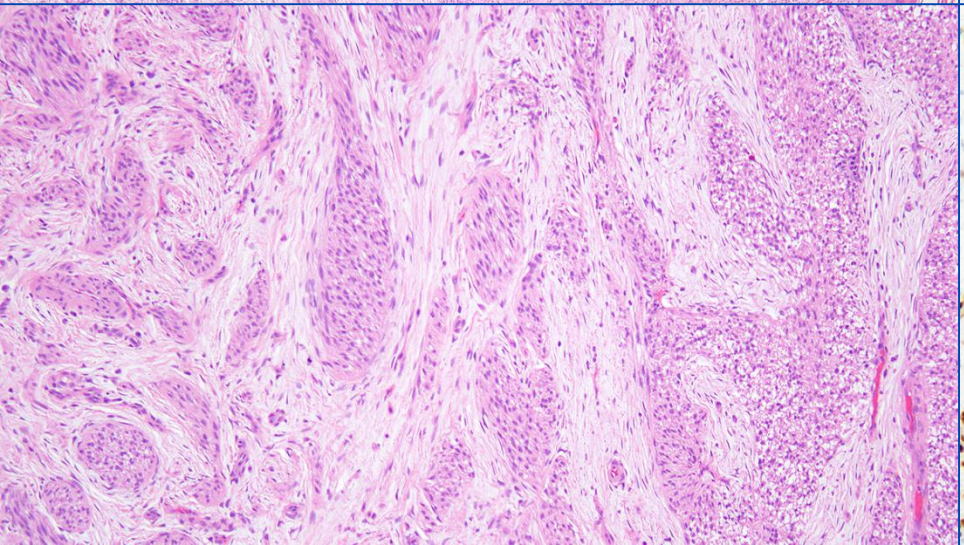

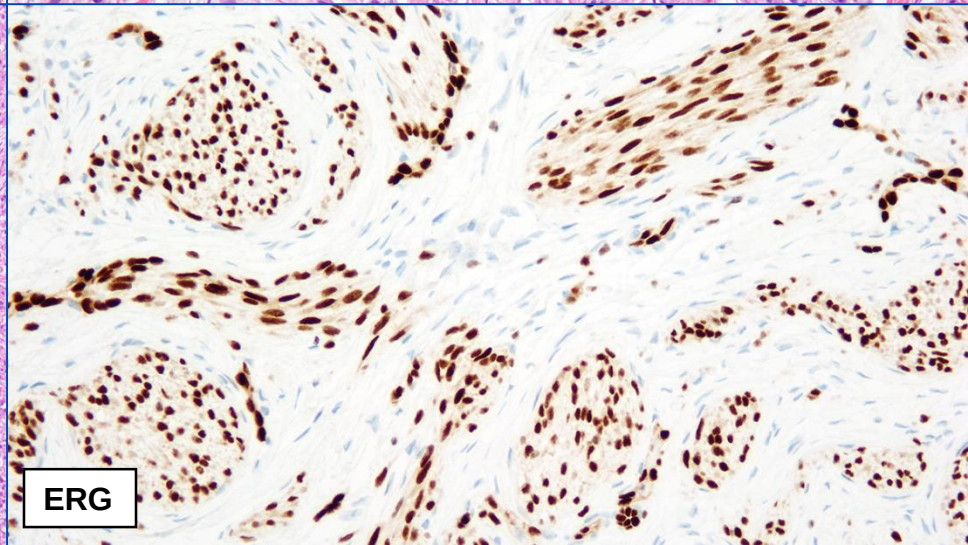
ERG

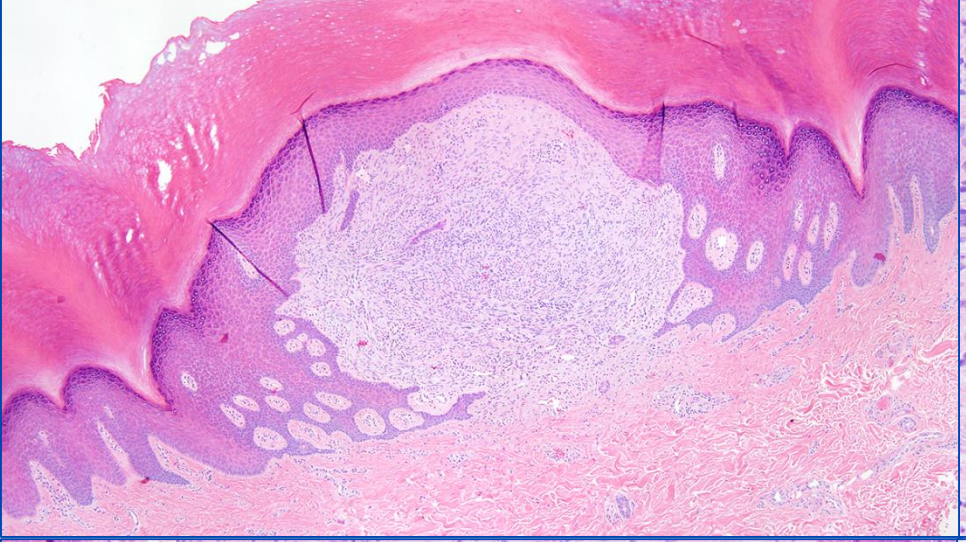

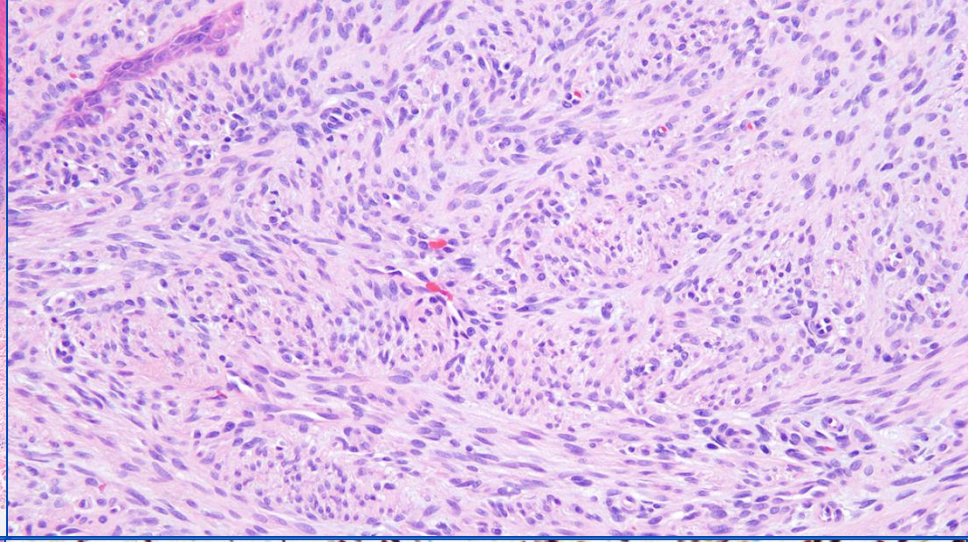

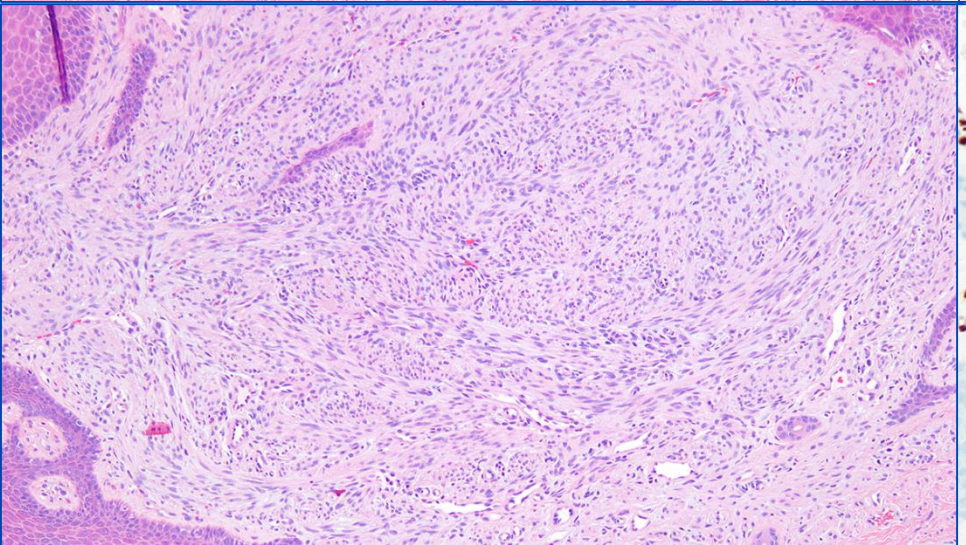

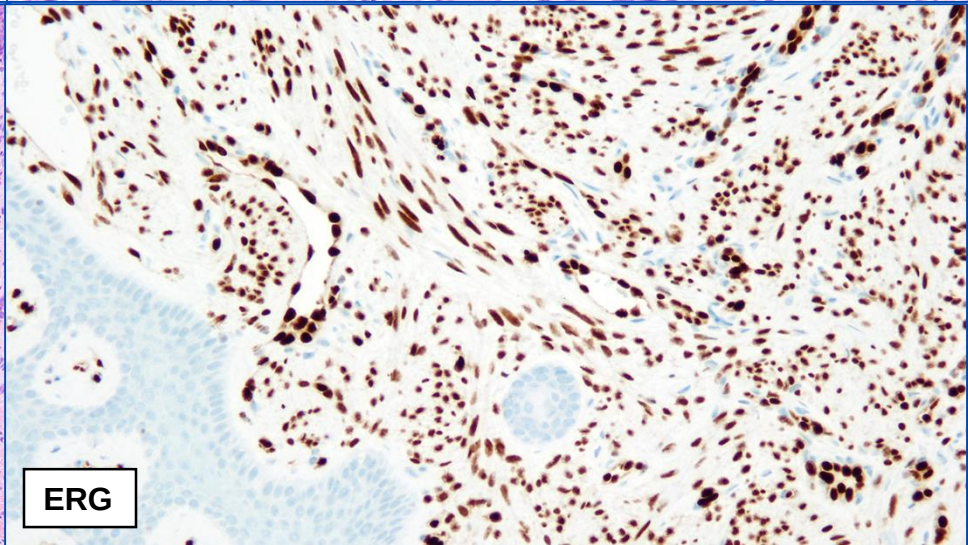
ERG

CAMTA1

- Calmodulin-binding transcription activator 1: transcription factor normally expressed only in the brain
- Epithelioid hemangioendothelioma most often harbors t(1;3)(p36;q23-25)(*WWTR1-CAMTA1)*
- Novus Biologicals polyclonal CAMTA1 antibody is a highly sensitive (85%) and specific marker of EHE
- Other CAMTA1 antibodies have much worse specificity
- CAMTA1 expression present in conventional and “high-grade” EHE

©2016 MFMER

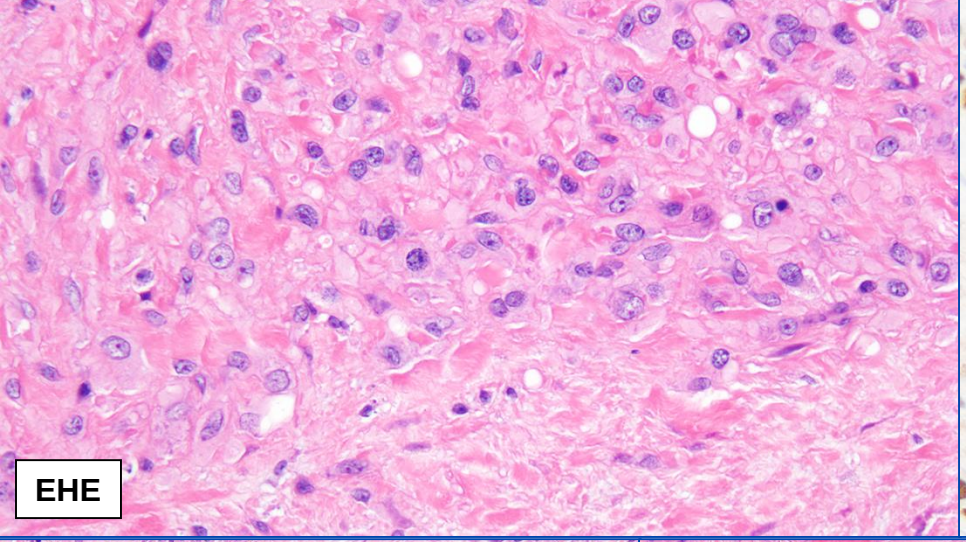
EHE

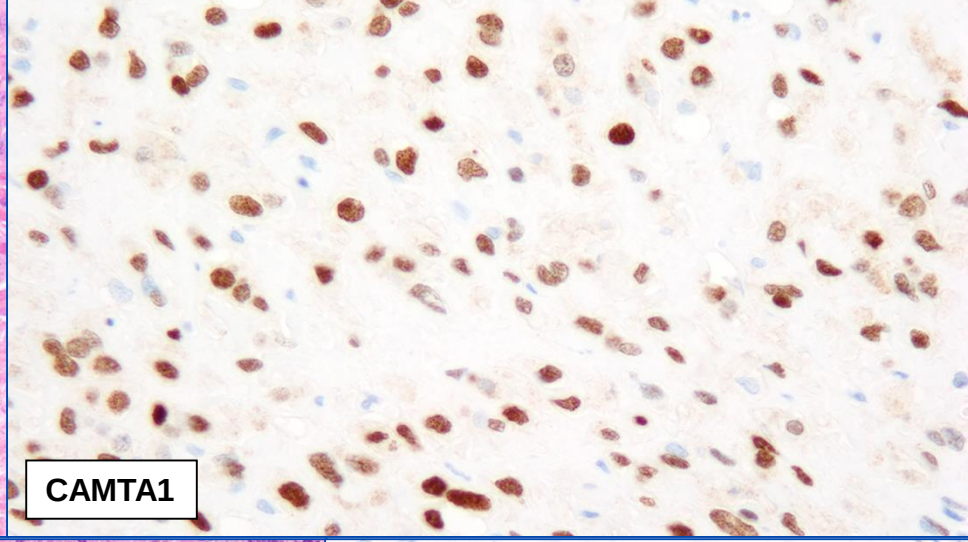
CAMTA1

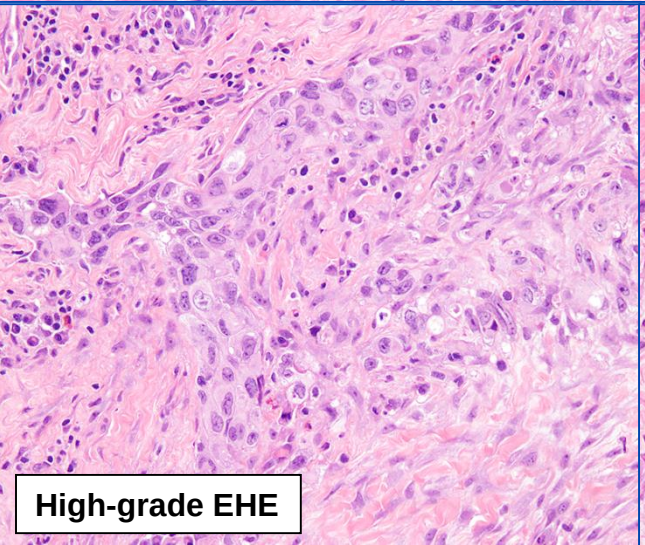
High-grade EHE

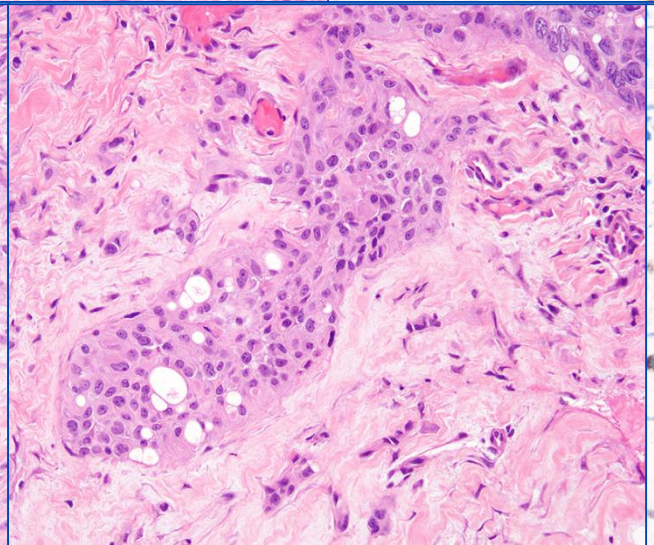

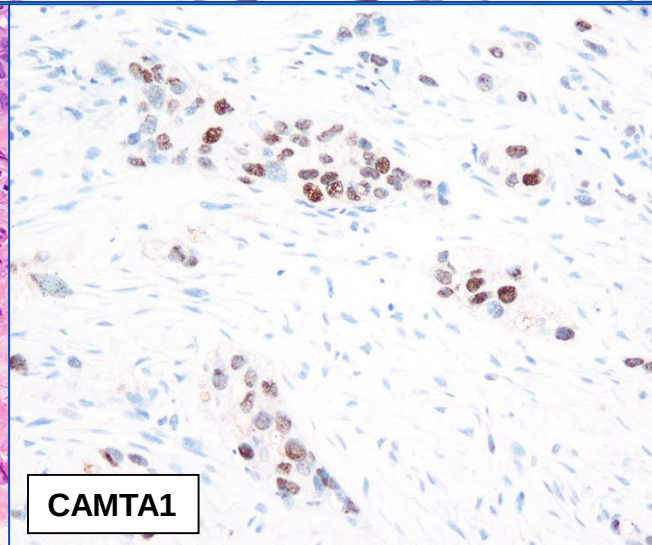
CAMTA1

FOSB

- Member of the Fos transcription factor family, involved in a oncogenesis and adaption to stress
- *SERPINE1-FOSB* fusions in pseudomyogenic hemangioendotheliomas
- *FOSB* rearrangements found in subsets of epithelioid hemangioma, in particular highly cellular/ atypical examples
- *FOSB* rearrangements are usually absent in cutaneous EH (ALHE)
- Diffuse FOSB expression present in >95% of PMHE
- Weaker expression occasionally present in angiosarcoma, EHE, and nodular/proliferative fasciitis

©2016 MFMER

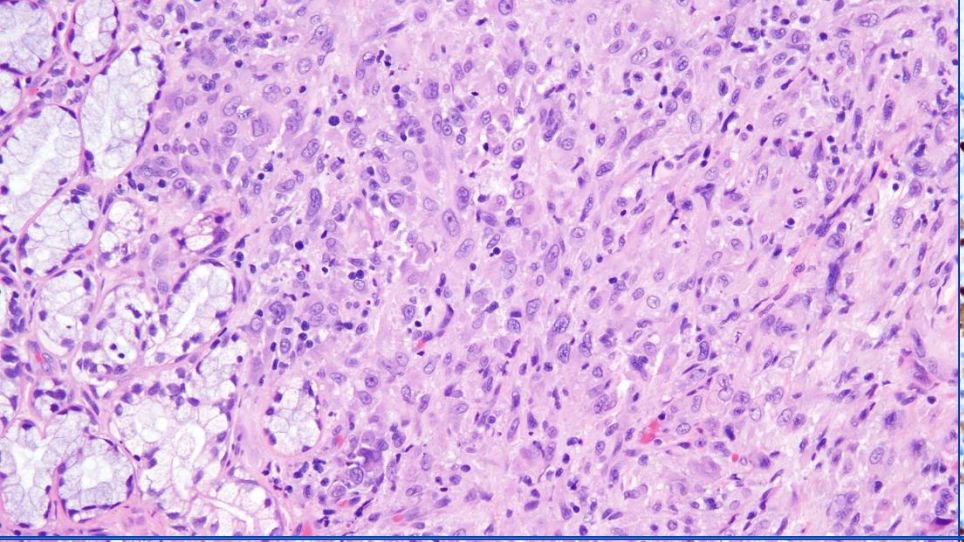

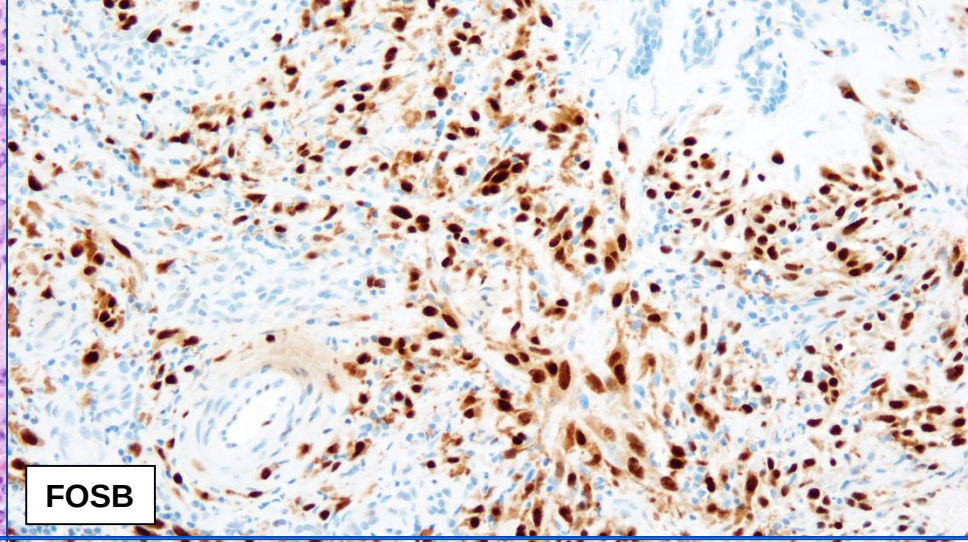
FOSB

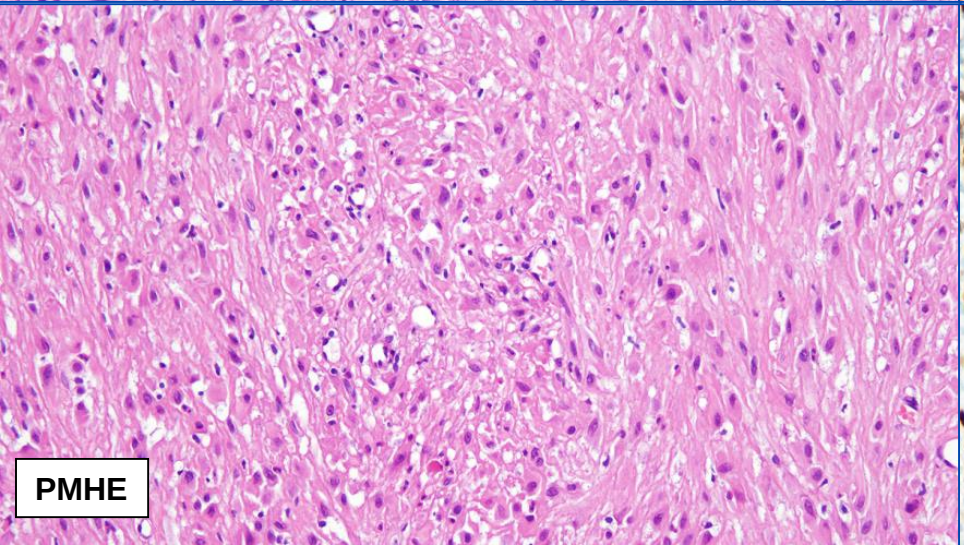
PMHE

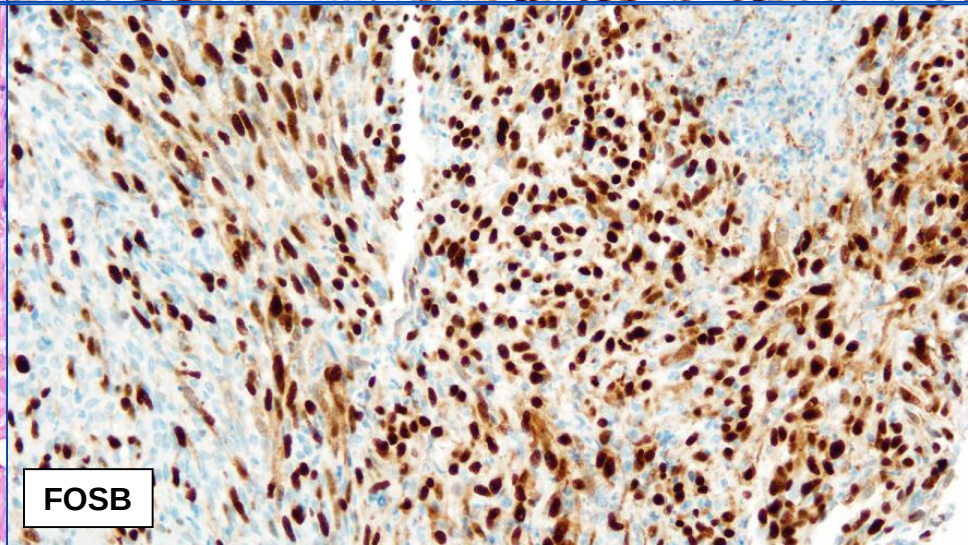
FOSB

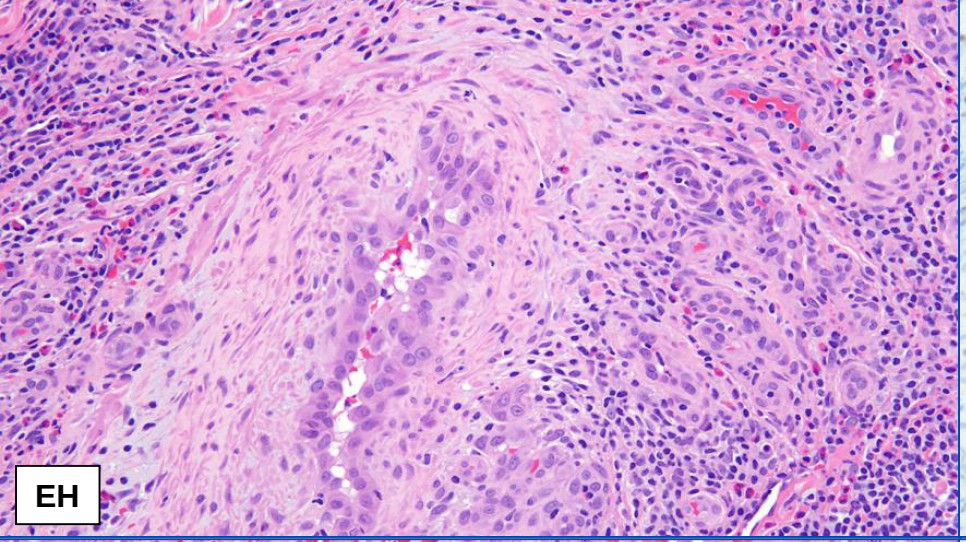
EH

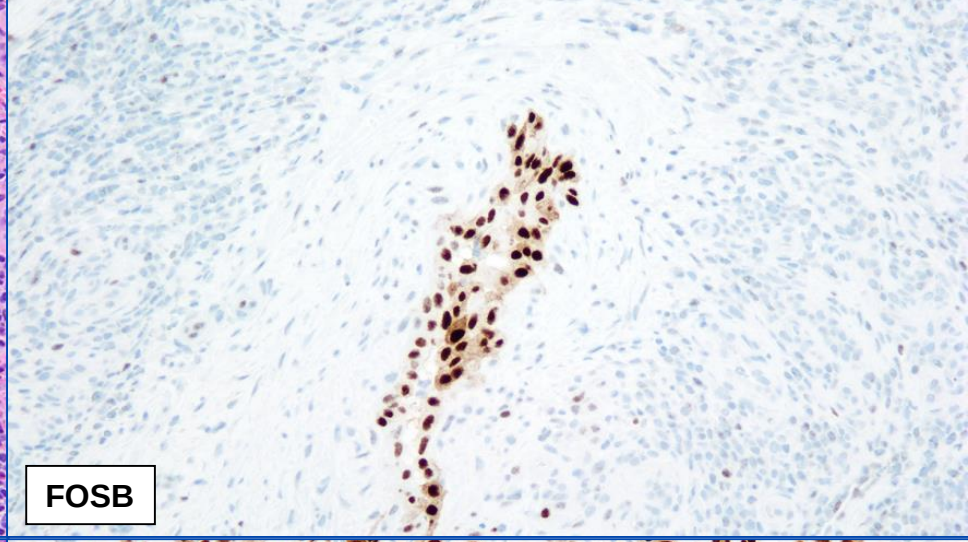
FOSB

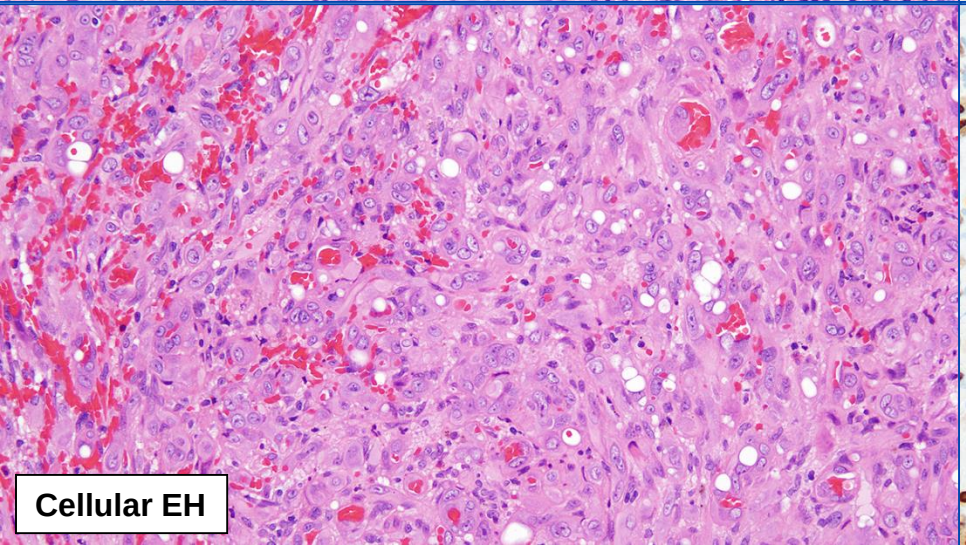
Cellular EH

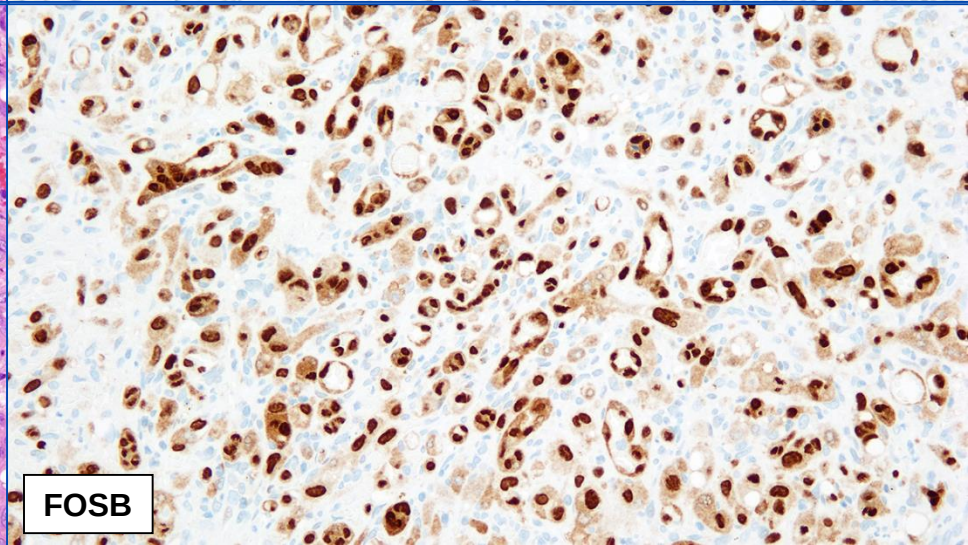
FOSB

Beta-catenin

- Involved in cadherin-mediated cellular cohesion and in Wnt-related intracellular signaling
- Loss of beta-catenin regulation by APC or beta-catenin mutations results in accumulation of cytosolic protein and eventual translocation to the nucleus
- Aberrant nuclear expression of beta-catenin seen in 70-90% of familial and sporadic desmoids
- Superficial fibromatoses lack beta-catenin mutations, but show aberrant nuclear expression in ~90% of cases
- Aberrant nuclear accumulation of β –catenin also seen in palisaded myofibroblastoma of lymph node, biphenotypic sinonasal sarcoma, sinonasal glomangiopericytoma, and in cranial fasciitis of childhood.

©2016 MFMER

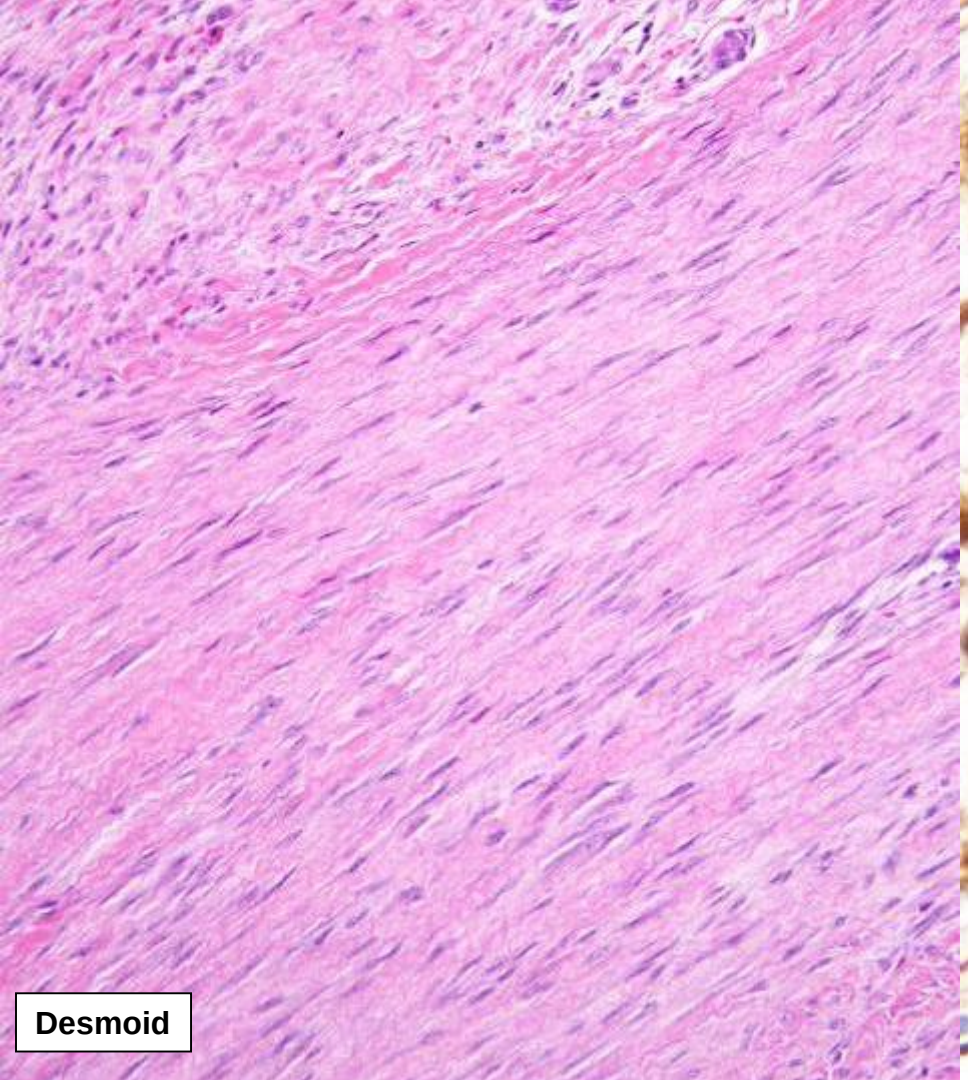
Desmoid

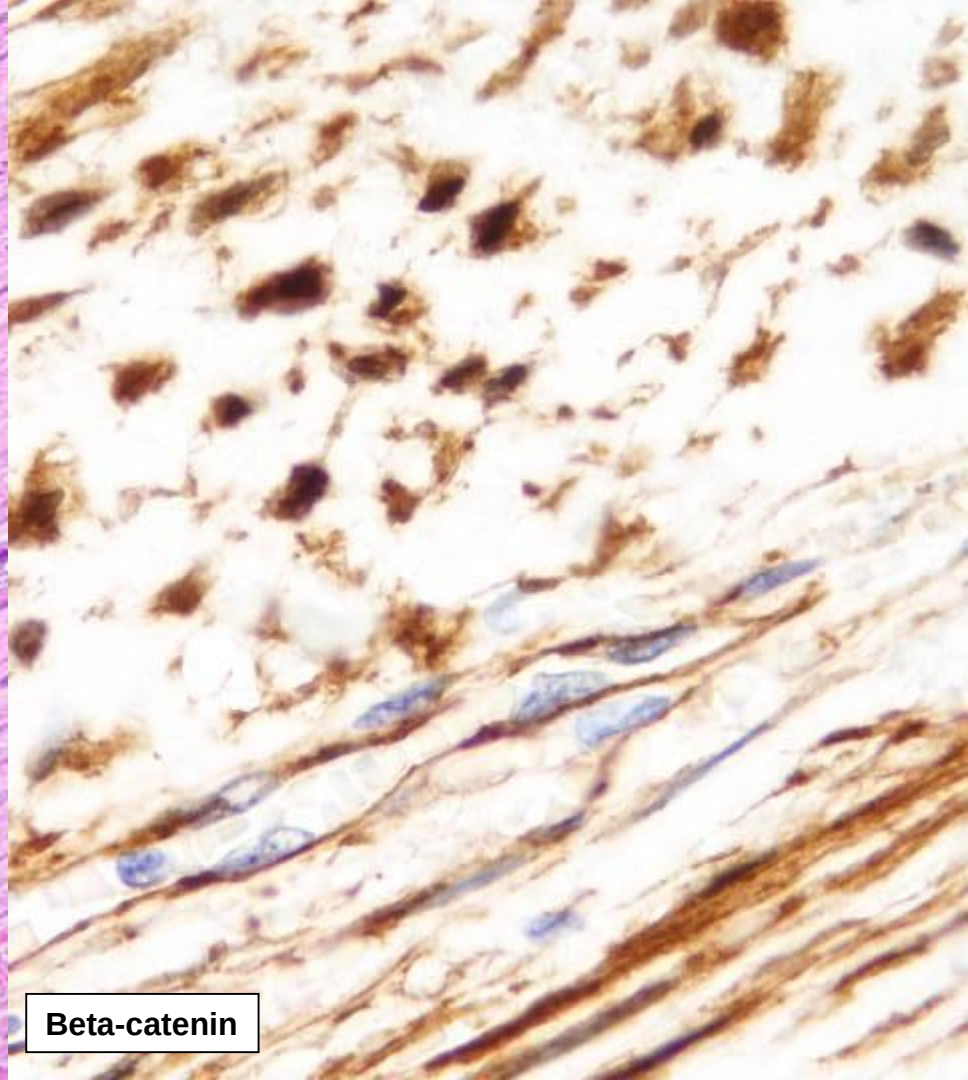
Beta-catenin

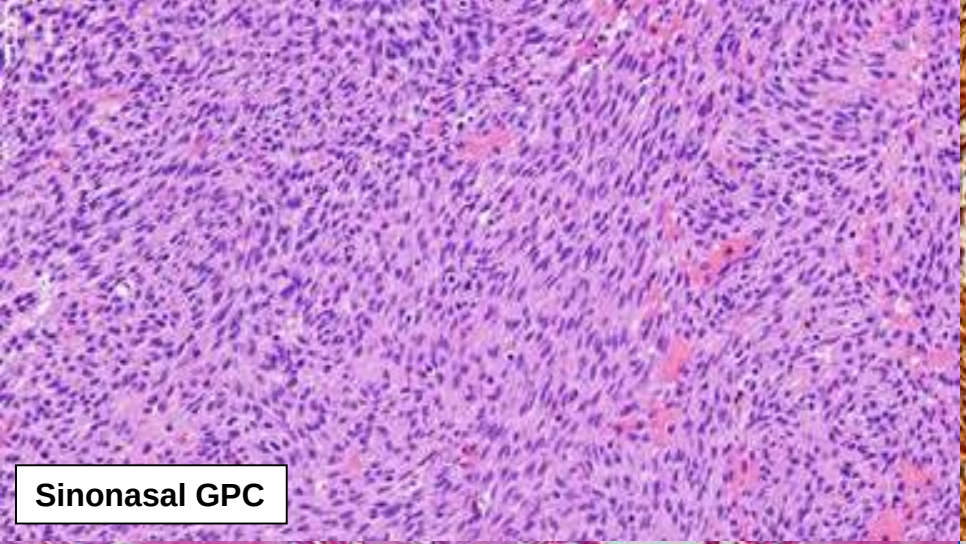
Sinonasal GPC

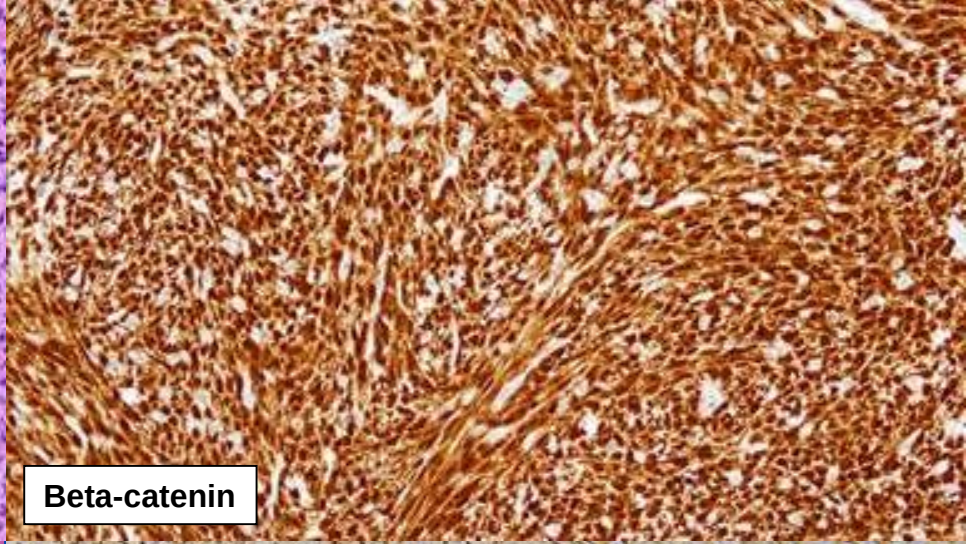
Beta-catenin

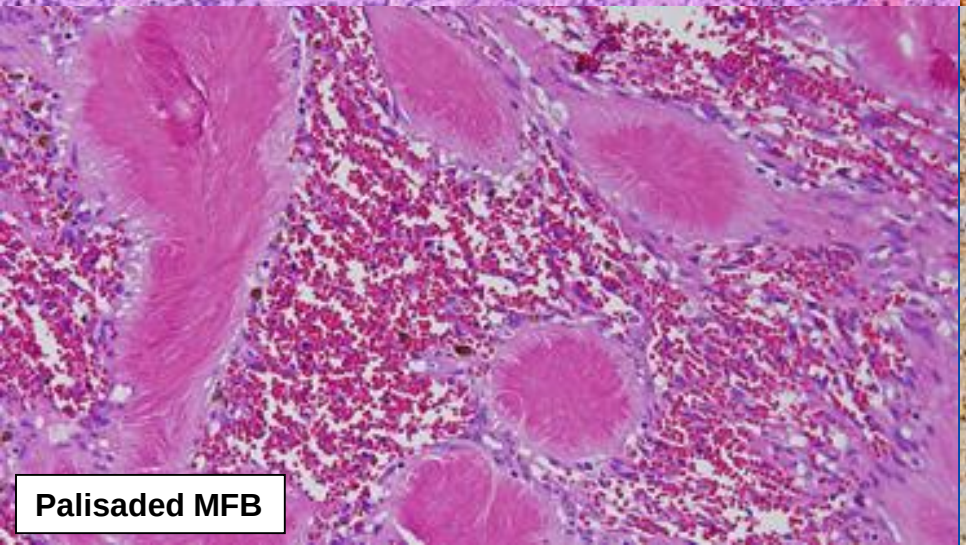
Palisaded MFB

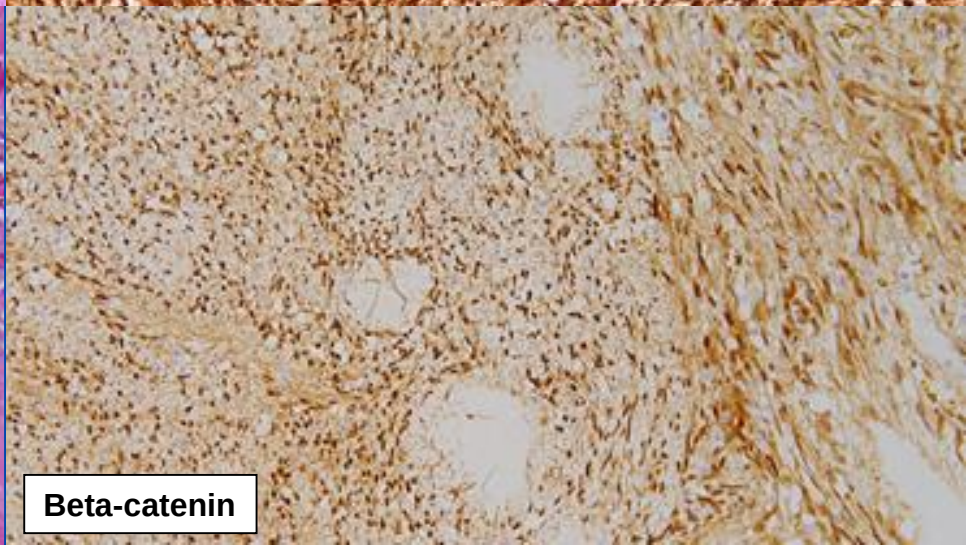
Beta-catenin

MUC4

- Transmembrane glycoprotein expressed in various epithelia, involved in cell surface protection and ErbB/HER2-mediated signaling
- Upregulated *MUC4* gene expression commonly seen in genetically confirmed low-grade fibromyxoid sarcoma and sclerosing epithelioid sarcoma
- *FUS-CREB3L2* (LGFMS, hybrid LGFMS/SEF); *EWSR1-CREB3L1* (SEF); rare “fusion-negative” cases
- Strong MUC4 expression present in essentially all LGFMS, SEF, and hybrid LGFMS/SEF, regardless of fusion type
- Rarely present in other tumor types (e.g., OFMT)

©2016 MFMER

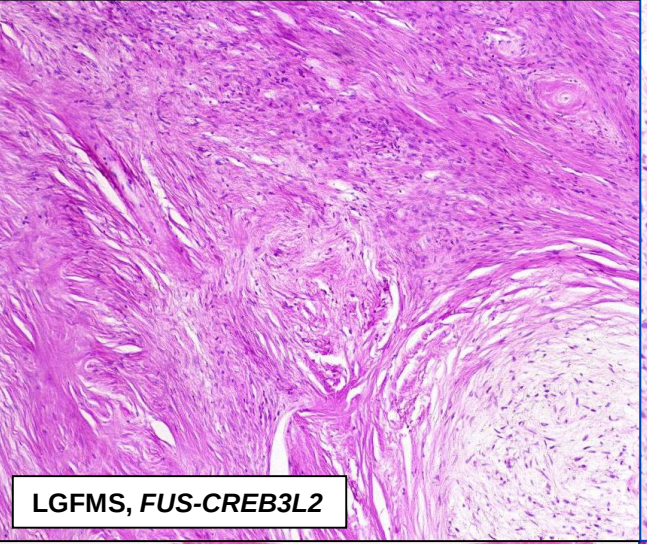

LGFMS, *FUS-CREB3L2*

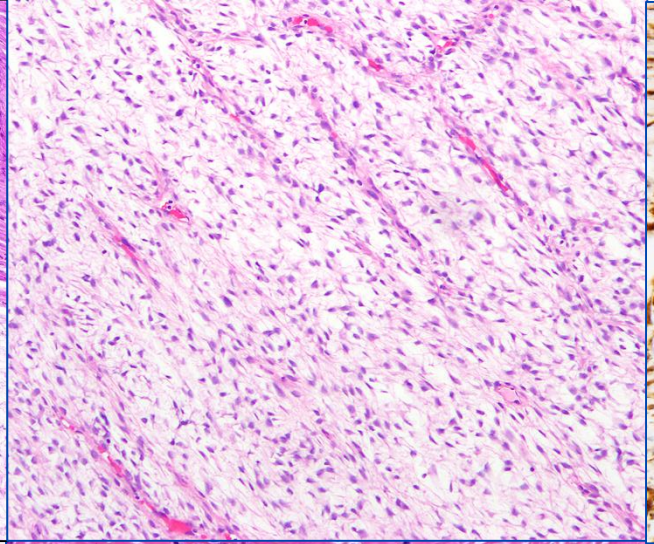

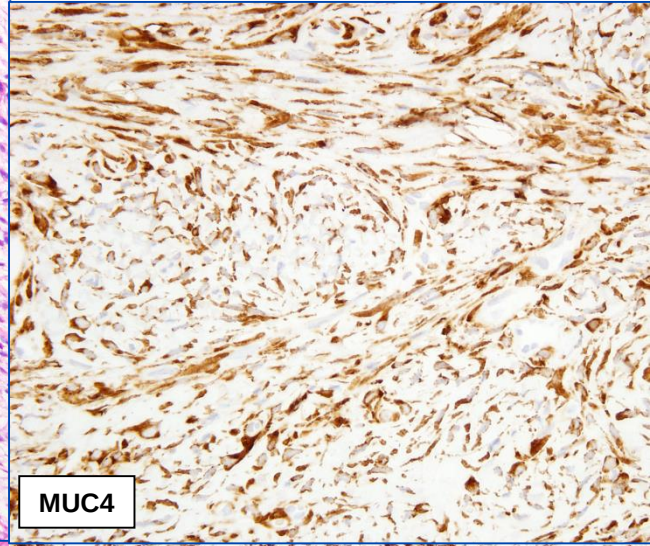

MUC4

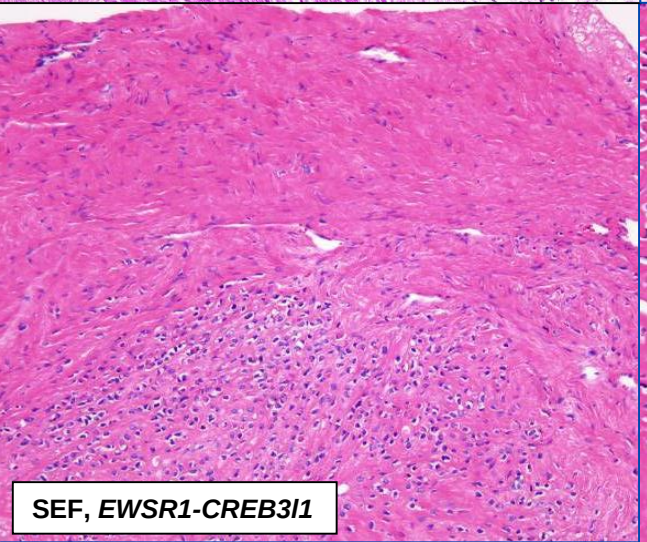

SEF, *EWSR1-CREB3l1*

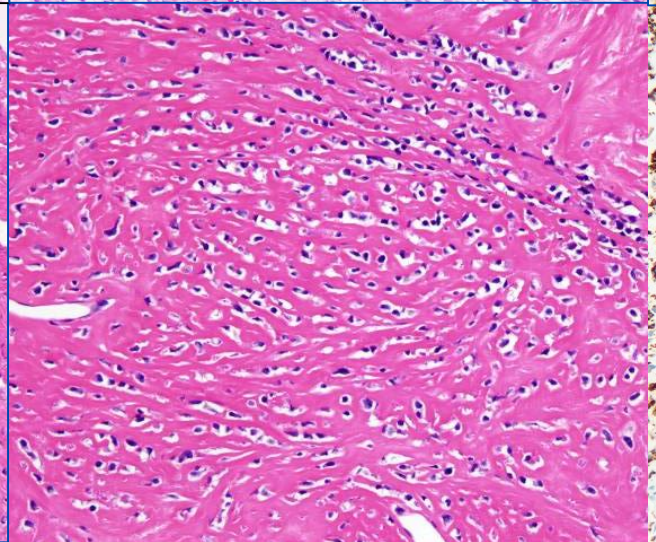

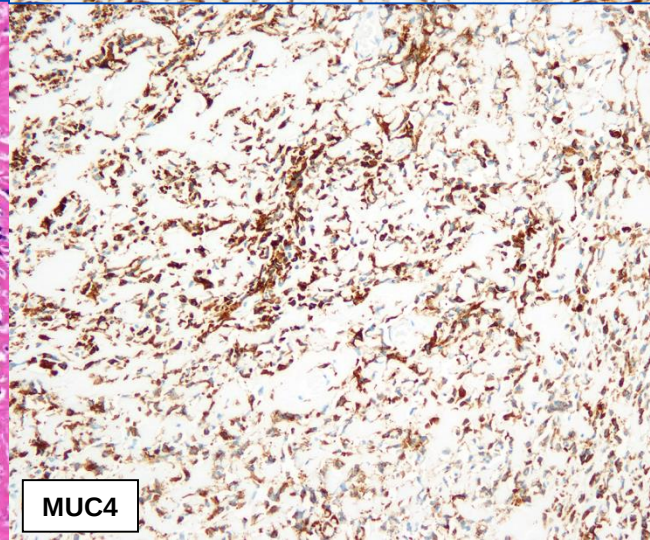

MUC4

PRKAR1A

- Tumor suppressor gene, mutated in approximately 40% of familial and sporadic Carney Complex cases
- Loss of heterozygosity and mutations of *PRKAR1A* present in a variety of Carney Complex-associated neoplasms
- Loss of PRKAR1A expression commonly seen in syndromic and non-syndromic malignant melanotic nerve sheath tumors, cutaneous myxomas and cardiac myxomas
- PRKAR1A loss is not a feature of conventional melanoma

©2016 MFMER

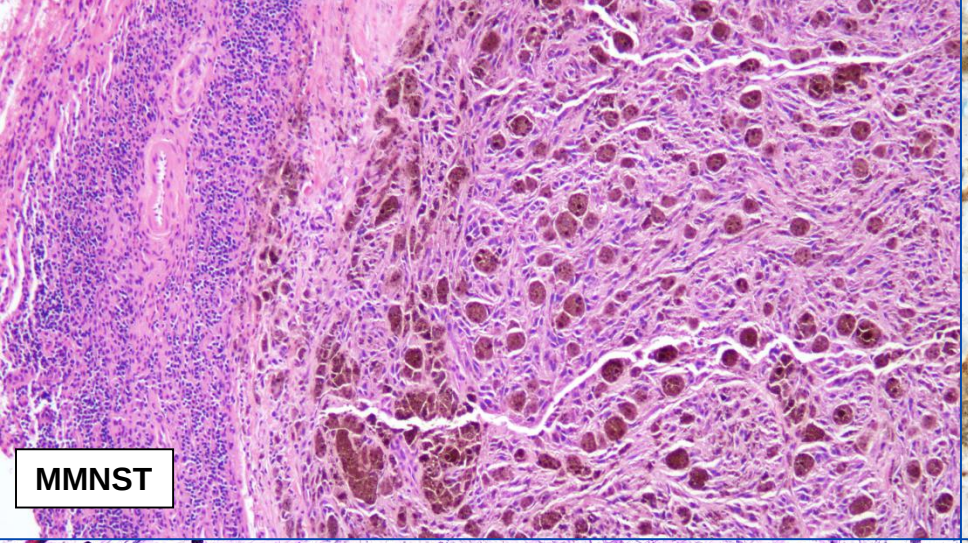
MMNST

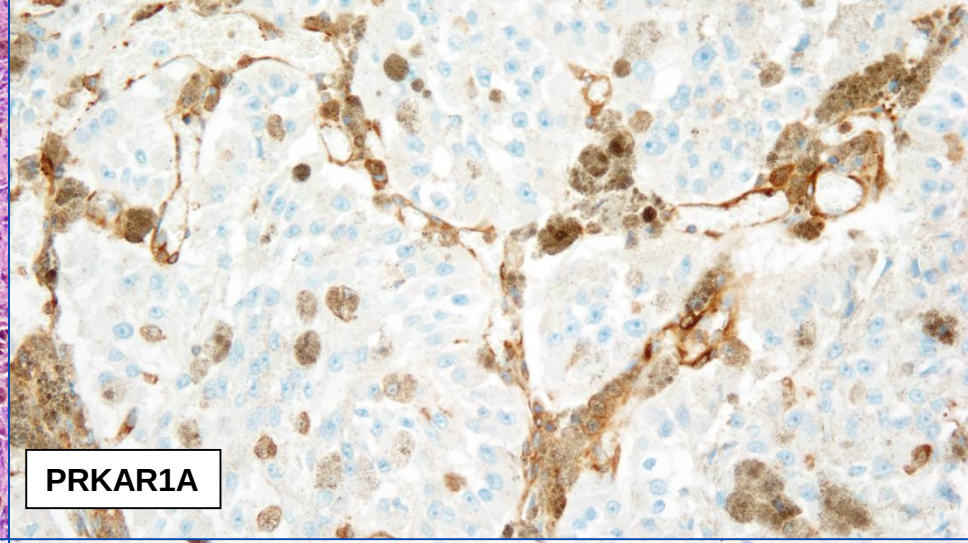
PRKAR1A

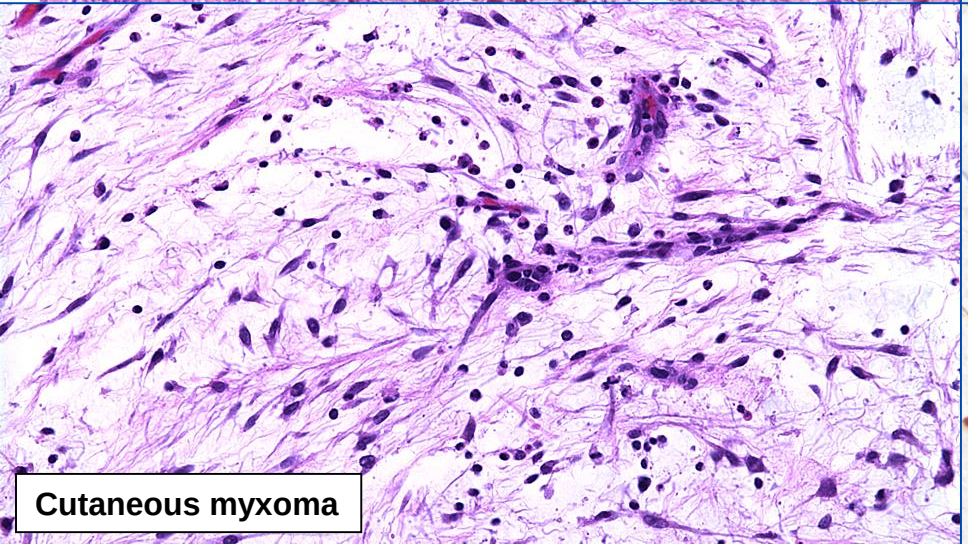
Cutaneous myxoma

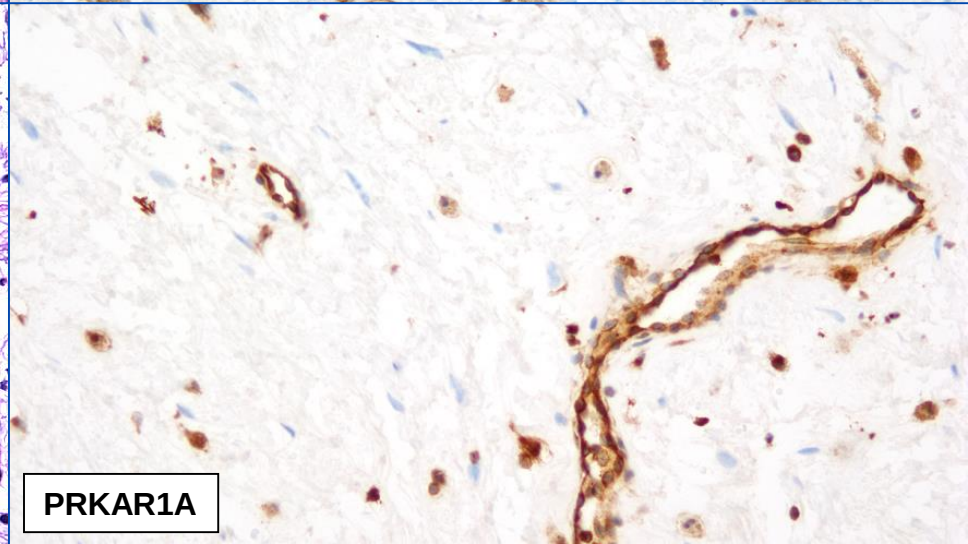
PRKAR1A

BCOR Sarcomas

- BCL6 transcriptional repressor
- *BCOR-CCNB3*, *BCOR-MAML3*, *BCOR* internal tandem duplications, *YWHAE-NUTM2B* and *ZC3H7B-BCOR*
- High *BCOR* mRNA expression
- Strong BCOR nuclear expression present in >95% of tumors showing *BCOR-CCNB3*, *BCOR-MAML3*, *BCOR* internal tandem duplications, and in related *YWHAE-NUTM2B* tumors
- BCOR expression also common in synovial sarcoma, but usually negative in other primitive sarcomas
- TLE1 expression

©2016 MFMER

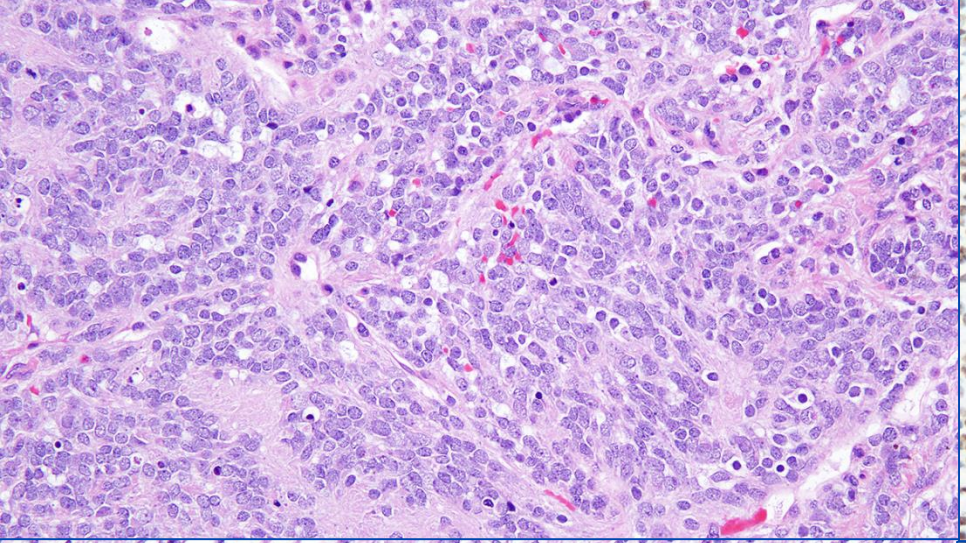

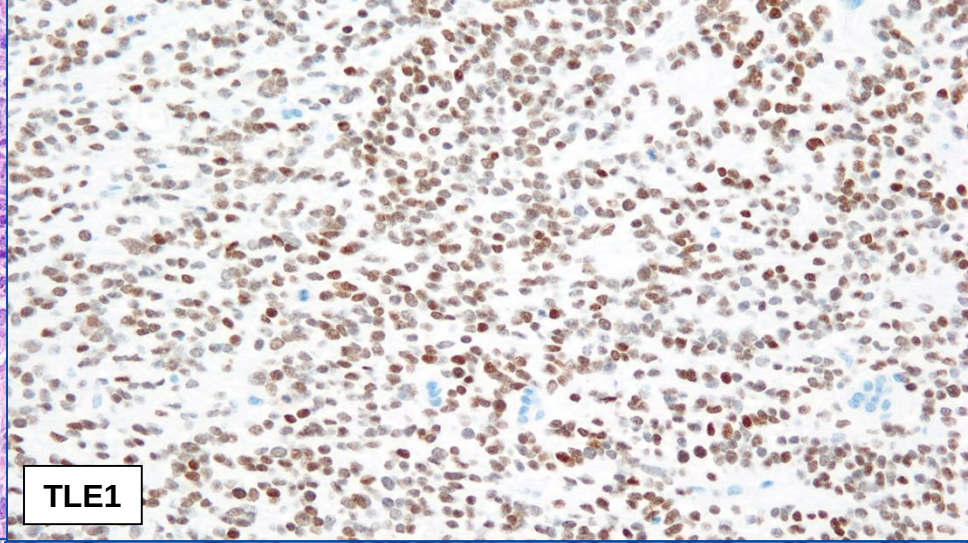
TLE1

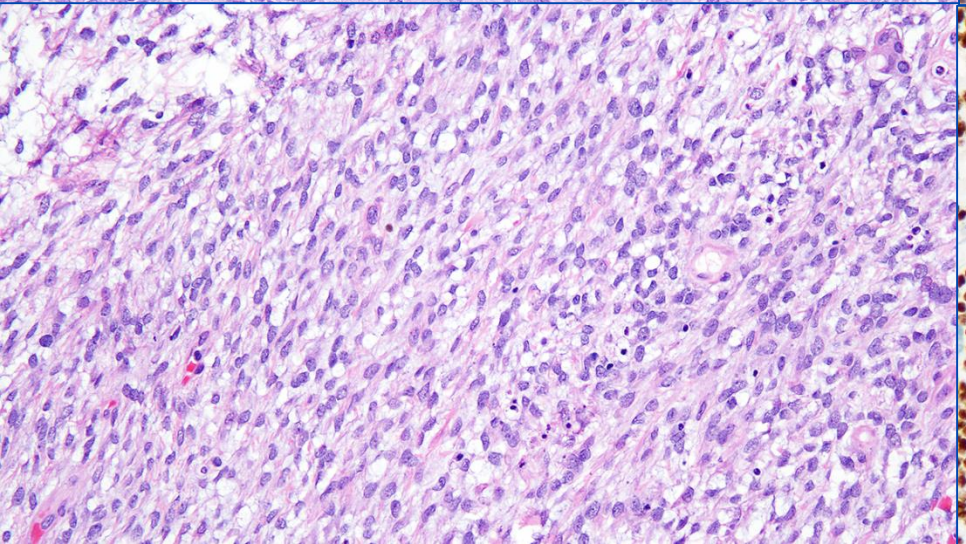

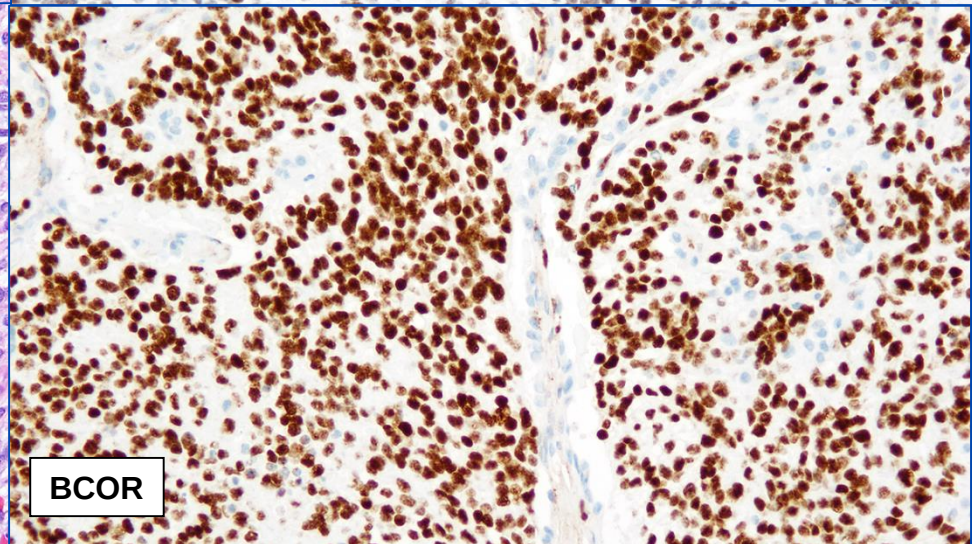
BCOR

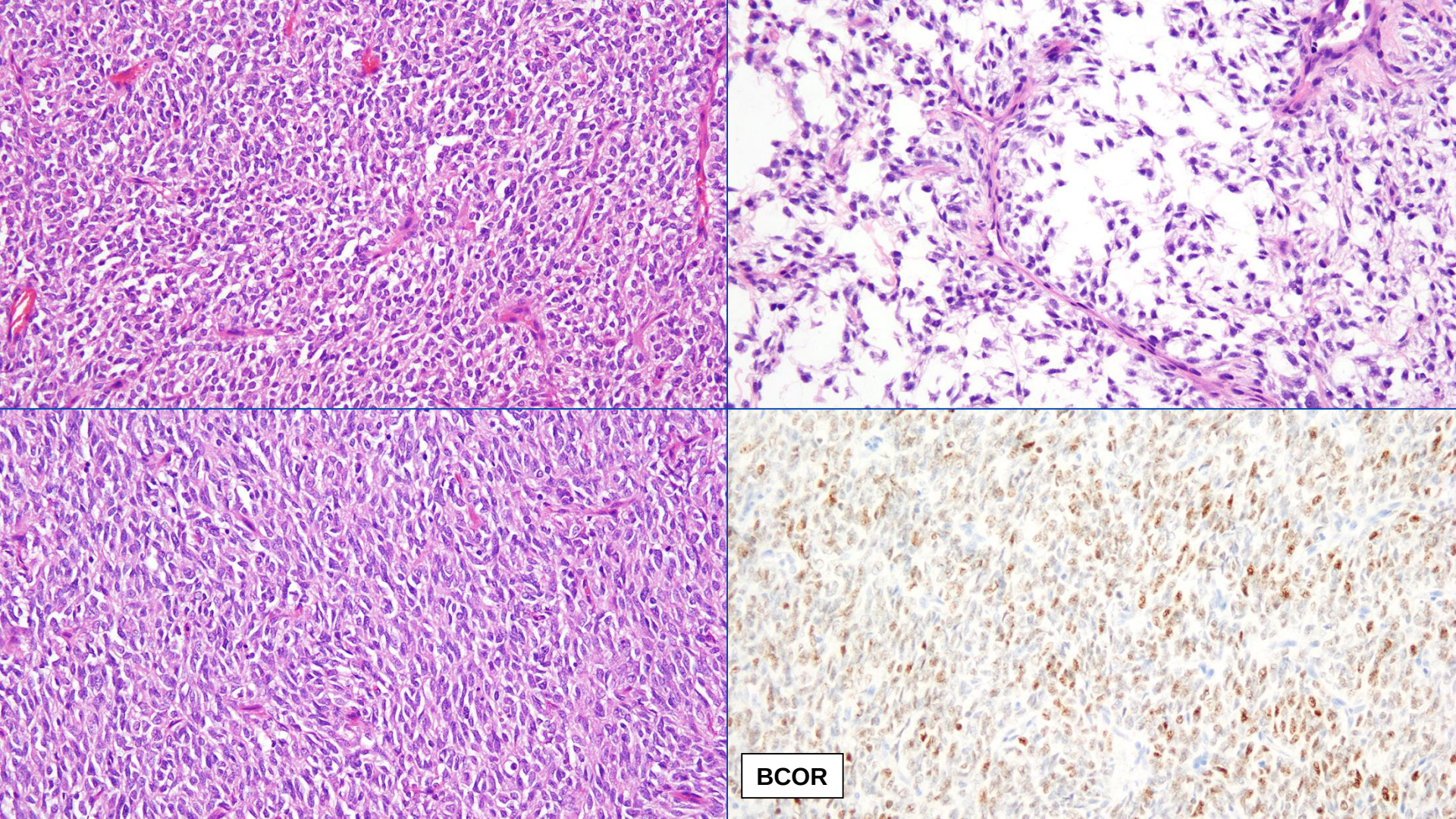
BCOR

CIC-rearranged Sarcomas

- t(4;19)(q35;q13.1) or t(10;19)(q26;q13.1)
- Overexpression of *ETV4* is a characteristic feature of *CIC*-rearranged sarcomas
- Positive in >90% of *CIC*-rearranged sarcomas and in only a very small minority of other primitive sarcomas
- *BCOR*-rearranged sarcomas are ETV4-negative
- *CIC*-rearranged sarcomas also commonly show patchy CD99 and nuclear WT1 (N-terminus) expression

©2016 MFMER

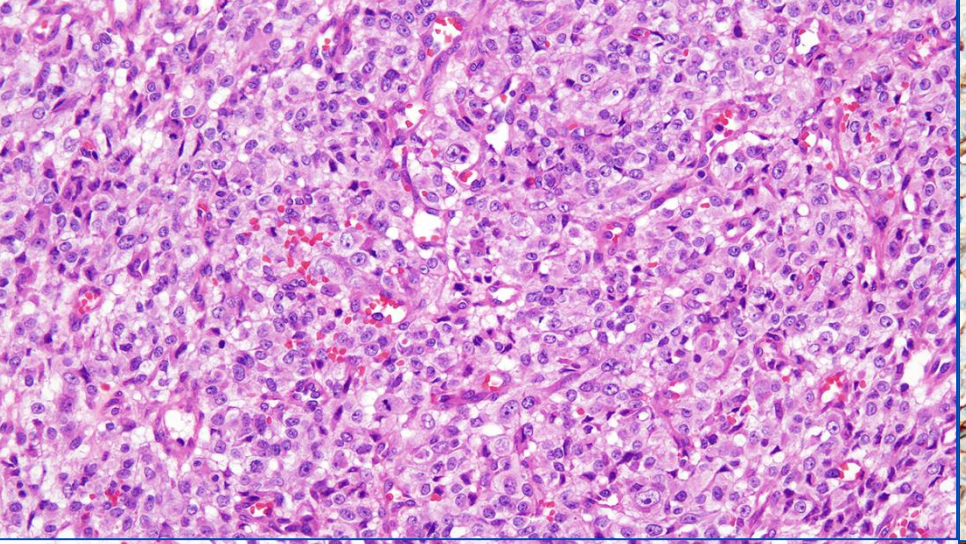

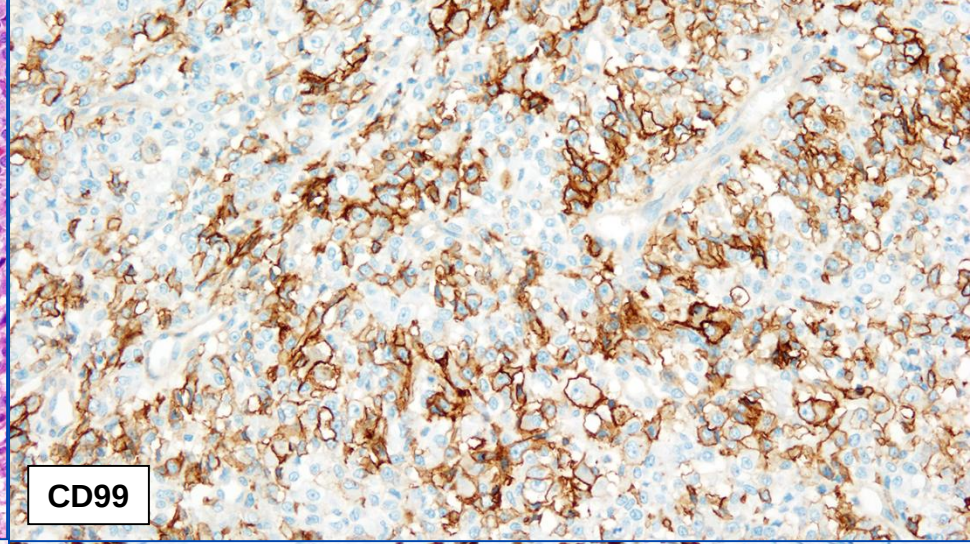
CD99

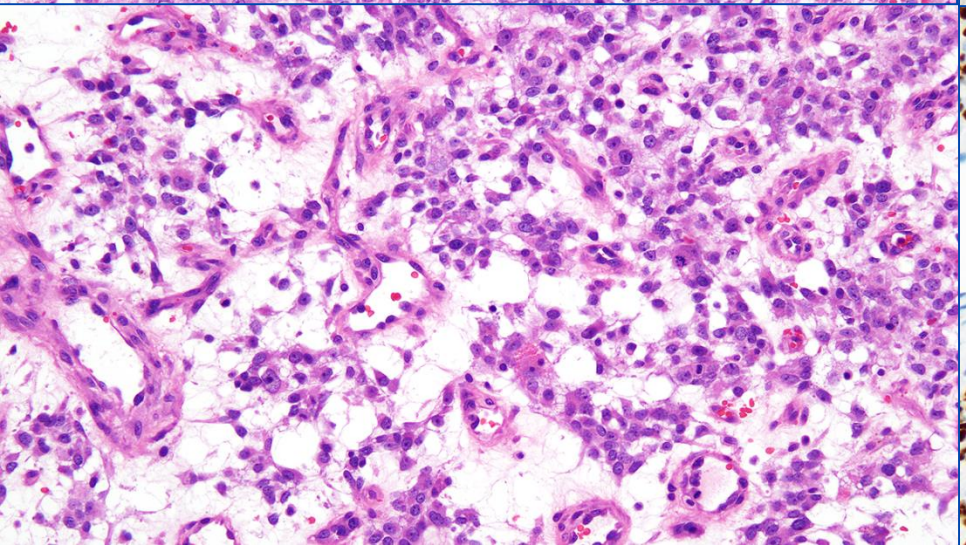

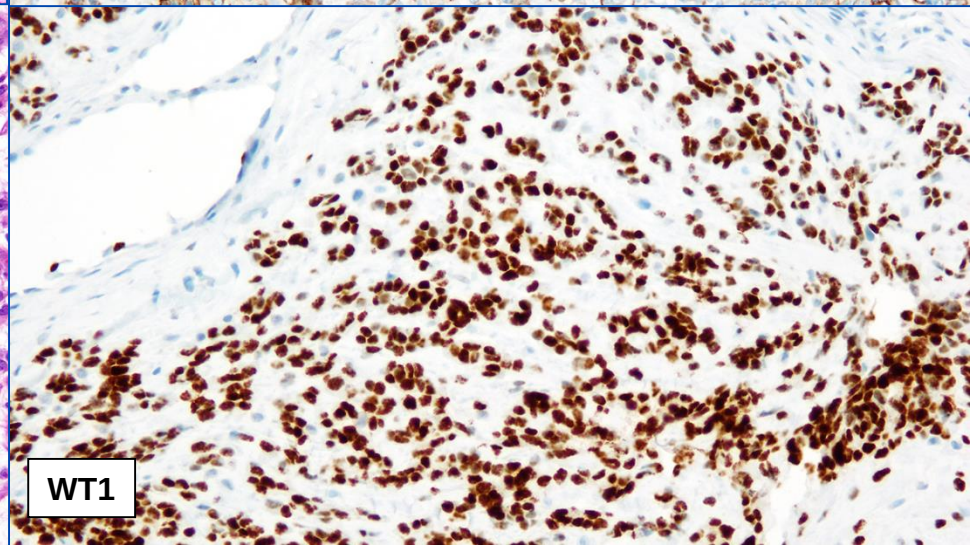
WT1

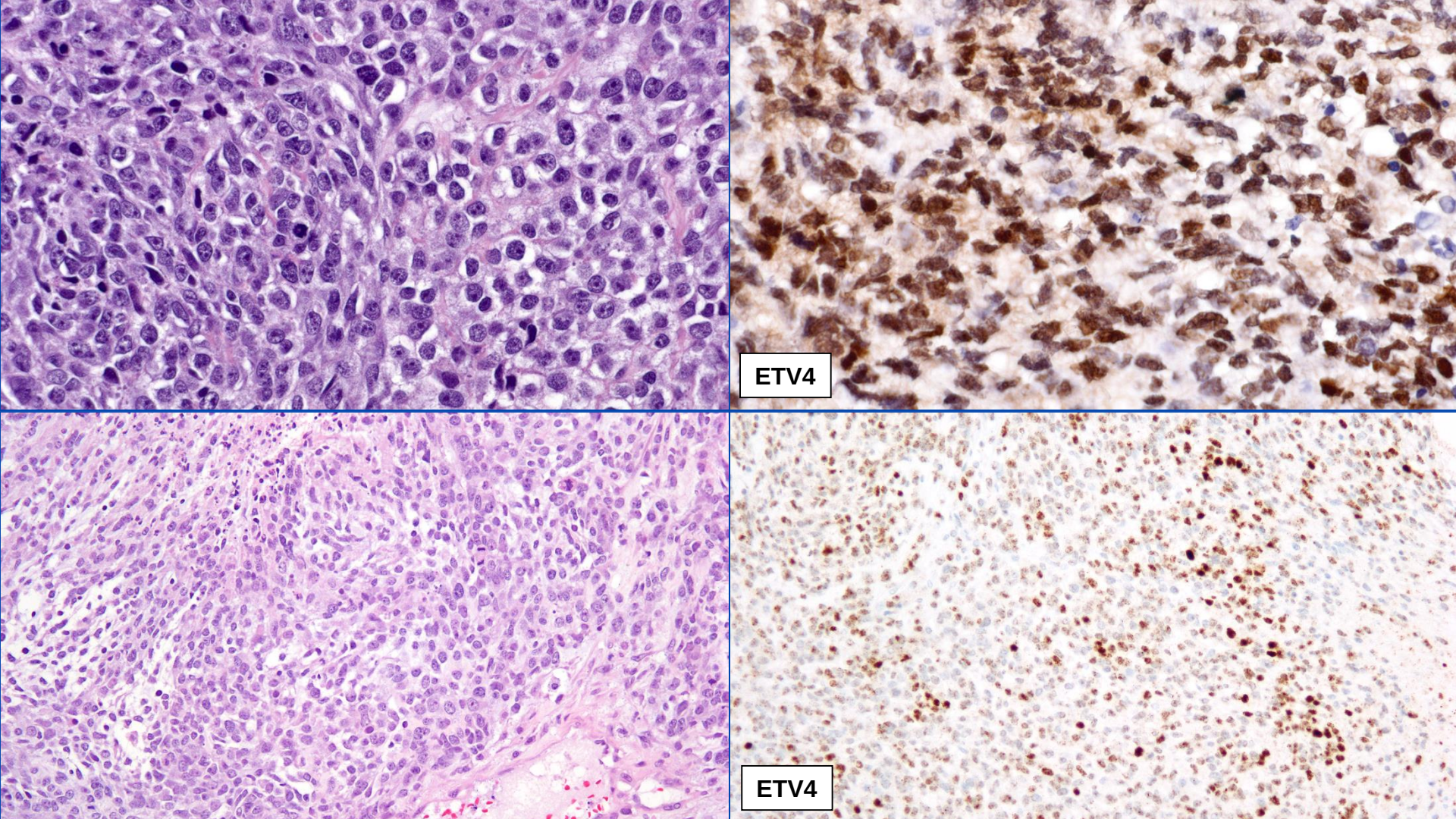
ETV4
ETV4

NTRK-fusion Positive Spindle Cell Tumors

- Emerging group of molecularly defined soft tissue tumors with variable morphology and grade
- Most often present in children
- Most often consist of monomorphic spindled cells with variable stromal hyalinization and infiltrative growth
- Most often harbor *NTRK1* fusions; rare cases with *NTRK2*, *NTRK3*, *RAF1* or *BRAF* fusions
- Typically S100 protein and CD34-positive, SOX10-negative
- Majority show cytoplasmic or nuclear positivity with pan-TRK monoclonal antibody
- Specificity of this antibody for NTRK-rearranged tumors is not yet clear
- Potential role for TRK-inhibitor therapy

©2016 MFMER

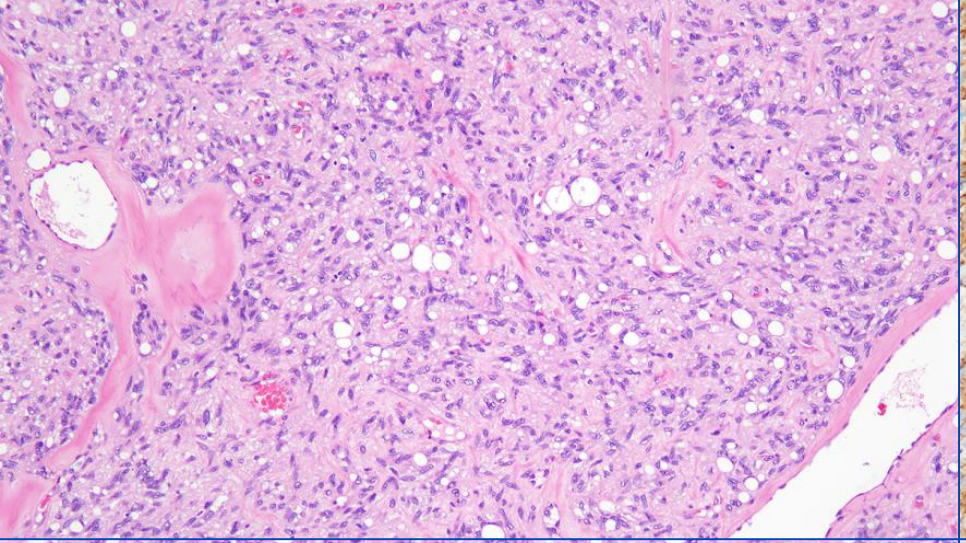

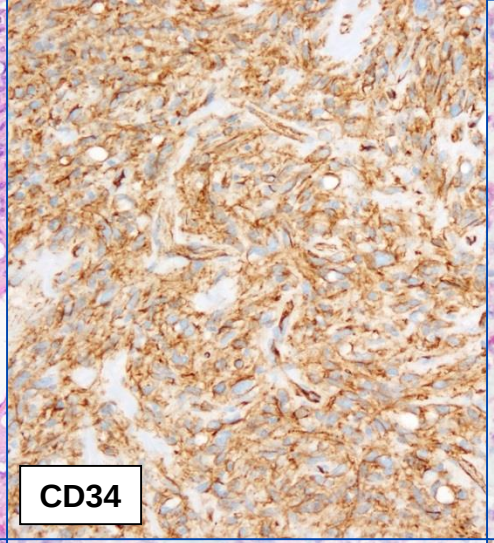
CD34

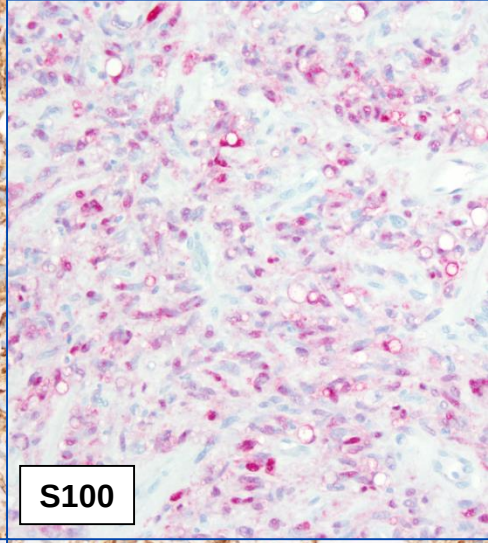
S100

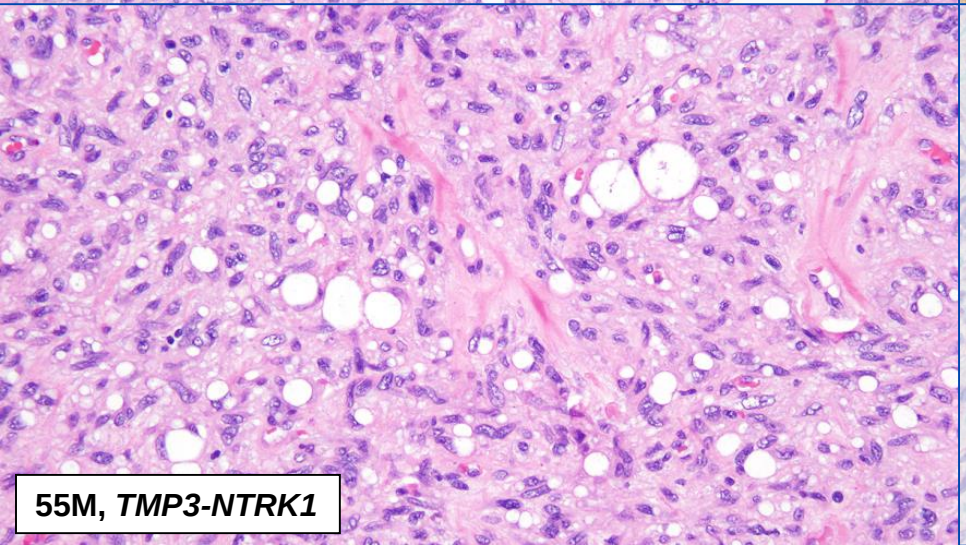
55M, *TMP3-NTRK1*

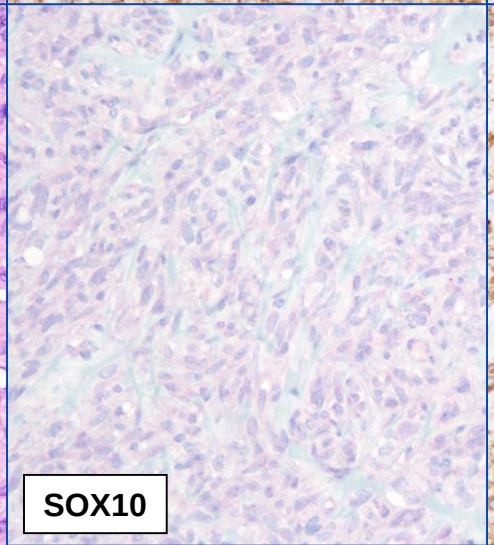
SOX10

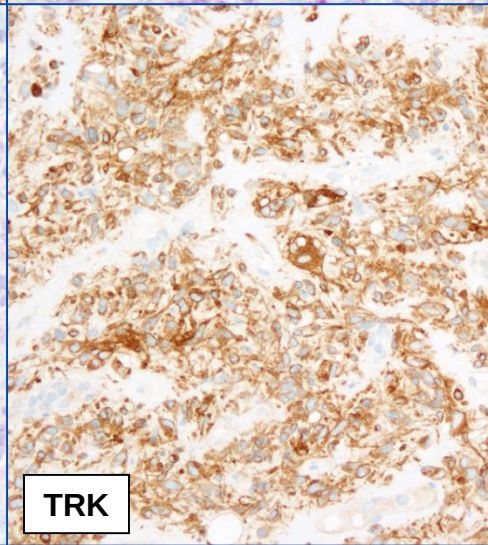
TRK

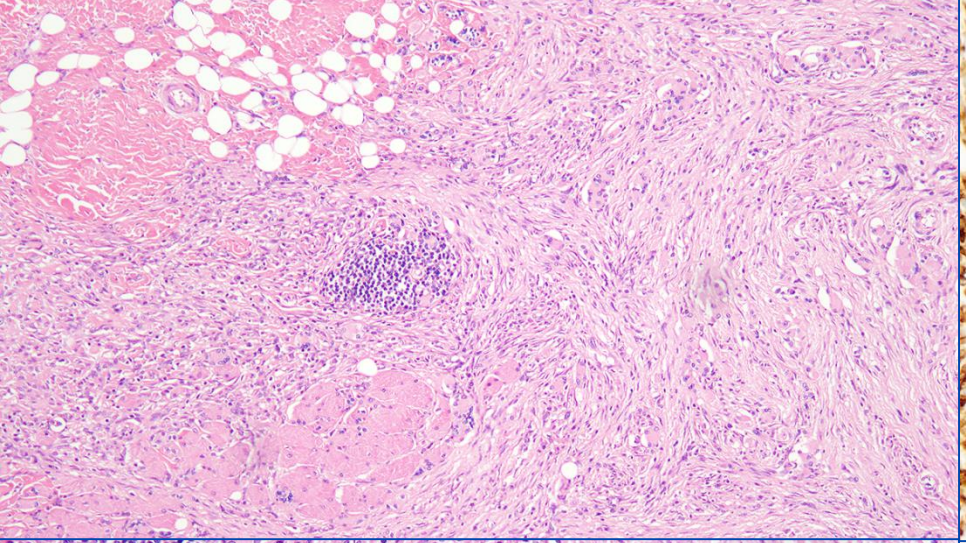

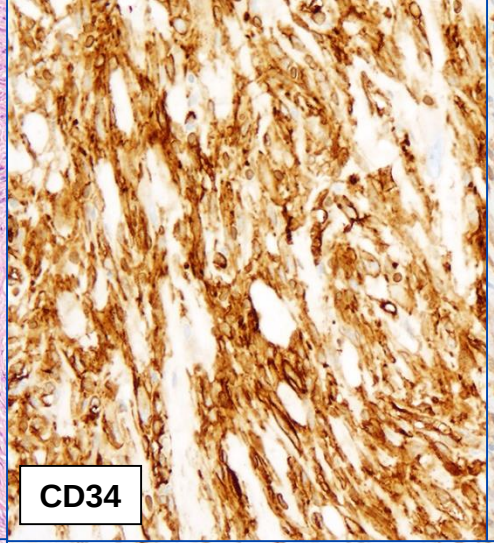
CD34

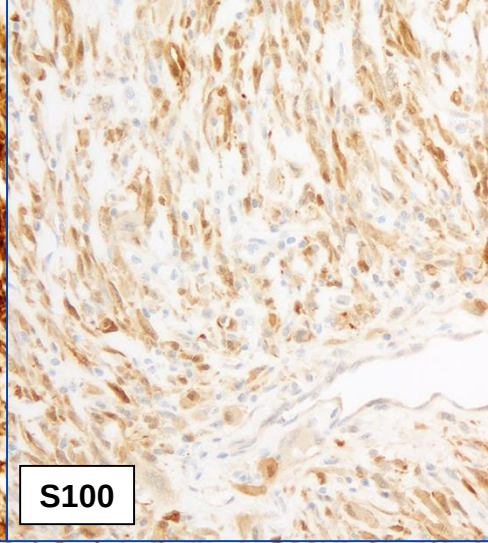
S100

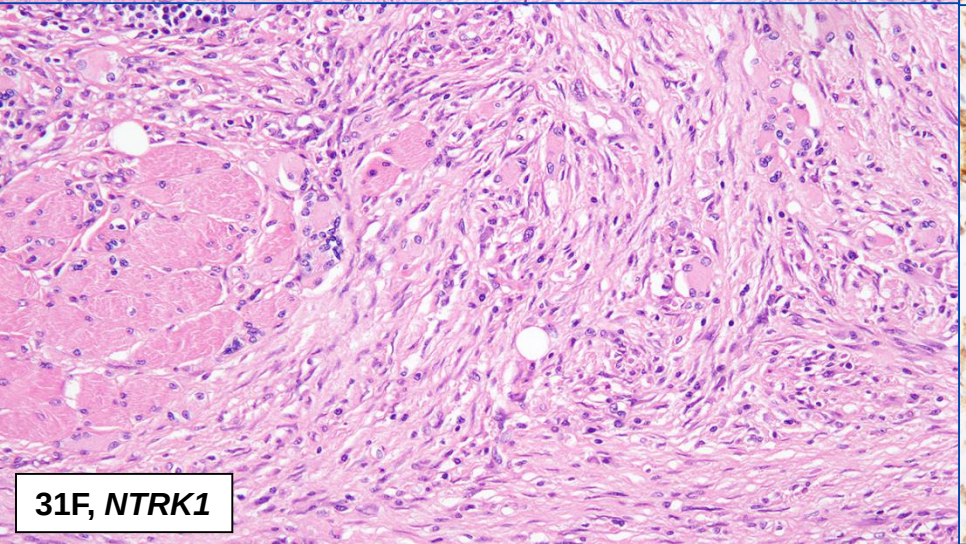
31F, *NTRK1*

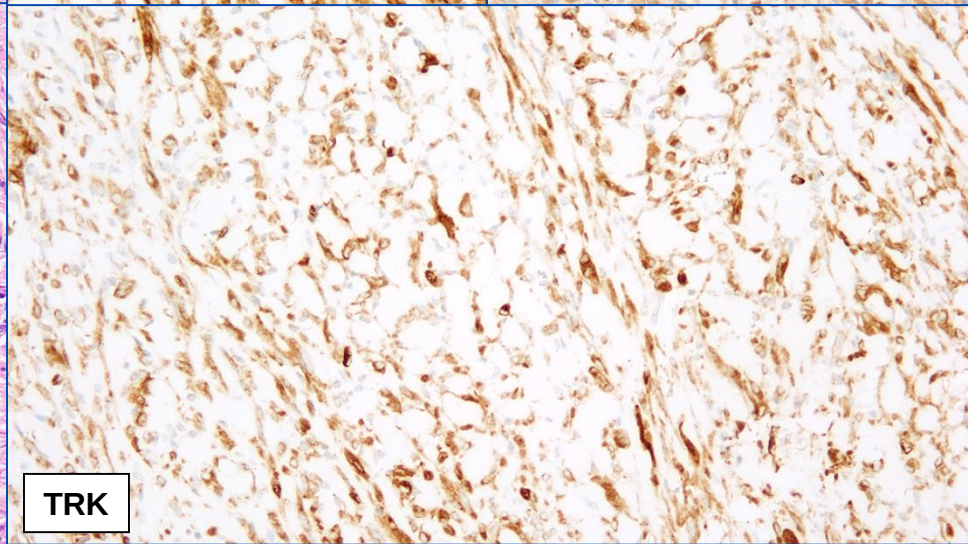
TRK

TLE1

- Member of *TLE* gene family, involved in hematopoiesis, neuronal differentiation and terminal epithelial differentiation
- Interacts with Wnt/β-catenin signaling pathway, important in synovial sarcoma pathogenesis
- Highly (>98%) sensitive, but imperfectly specific marker of synovial sarcoma
- Best used as a screening marker or in cases where molecular tests are not available
- May also be a clue to the diagnosis of MPNST (patchy) and BCOR sarcoma

©2016 MFMER

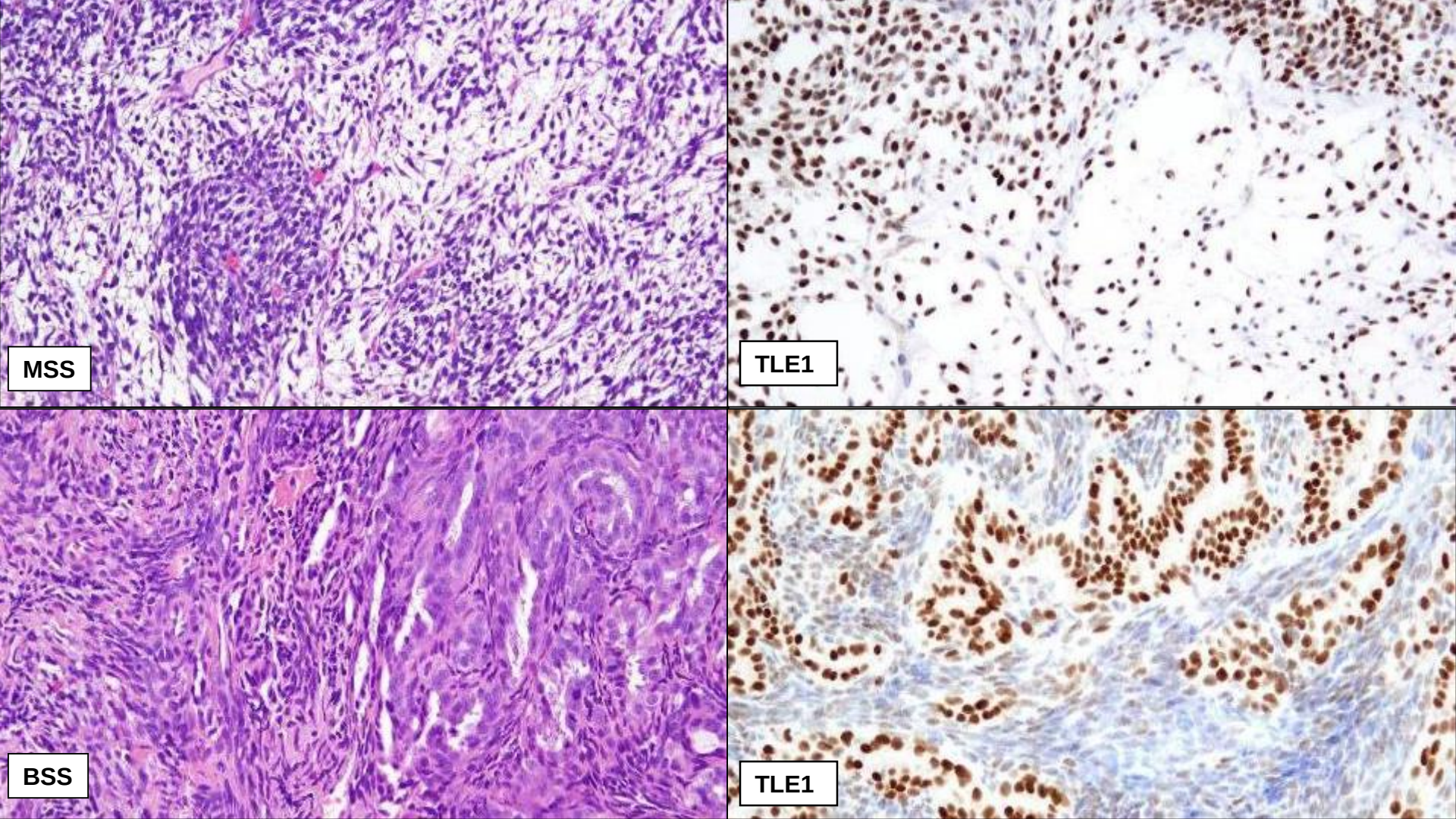
MSS
TLE1
BSS
TLE1

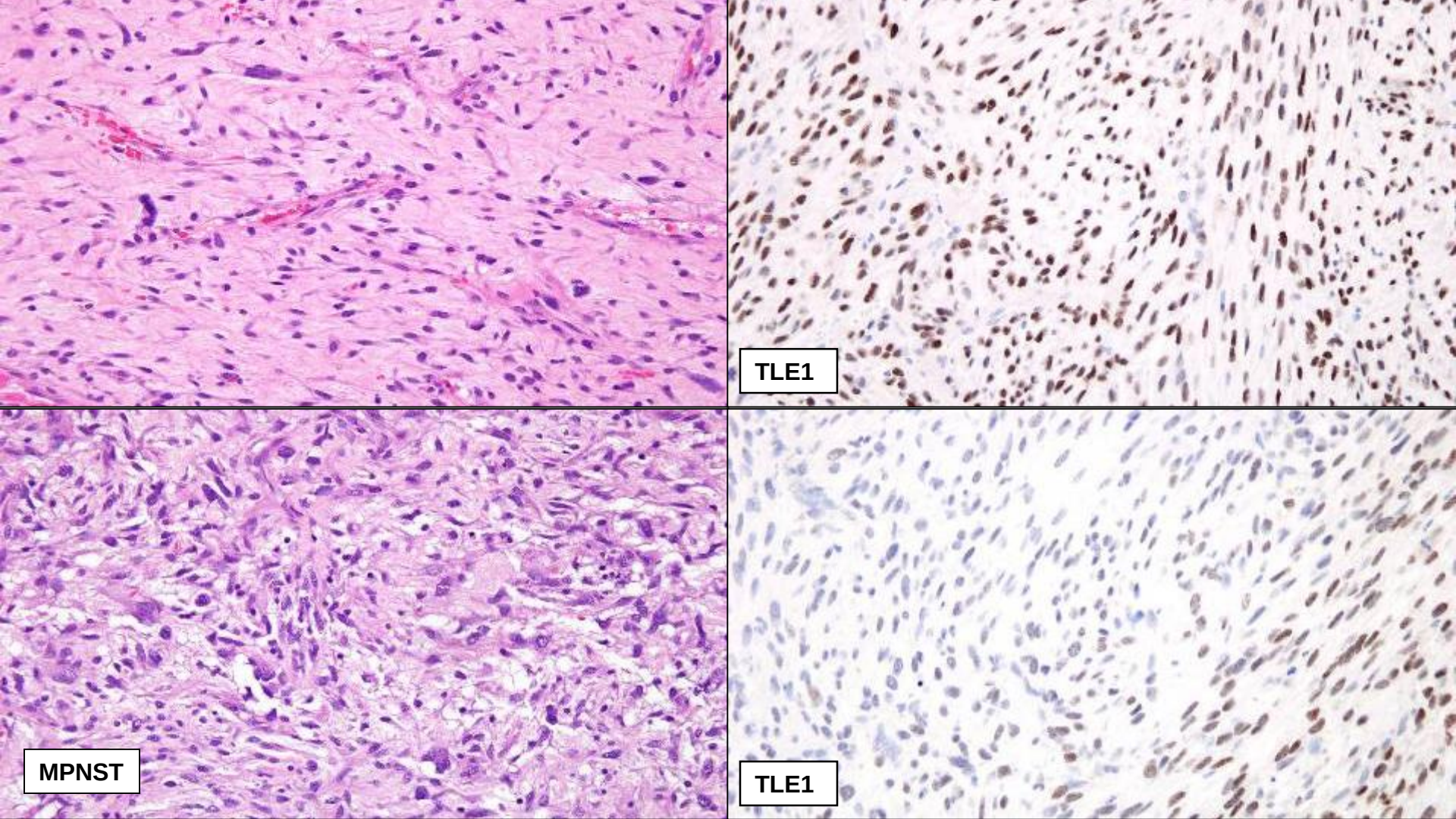
TLE1
MPNST
TLE1

TFE3

- Alveolar soft part sarcoma
  - der(17)t(X;17) (p11;q25)(*ASPSCR1-TFE3*)
- Xp11-renal cell carcinoma
- TFE3 antibodies initially reported as highly sensitive and specific
- More recent data shows TFE3 IHC to have very poor specificity for *TFE3*-rearranged neoplasia
- Highly method dependent
- TFE3 IHC should only be used as a screening marker to identify tumors likely to be *TFE3*-rearranged by molecular methods

©2016 MFMER

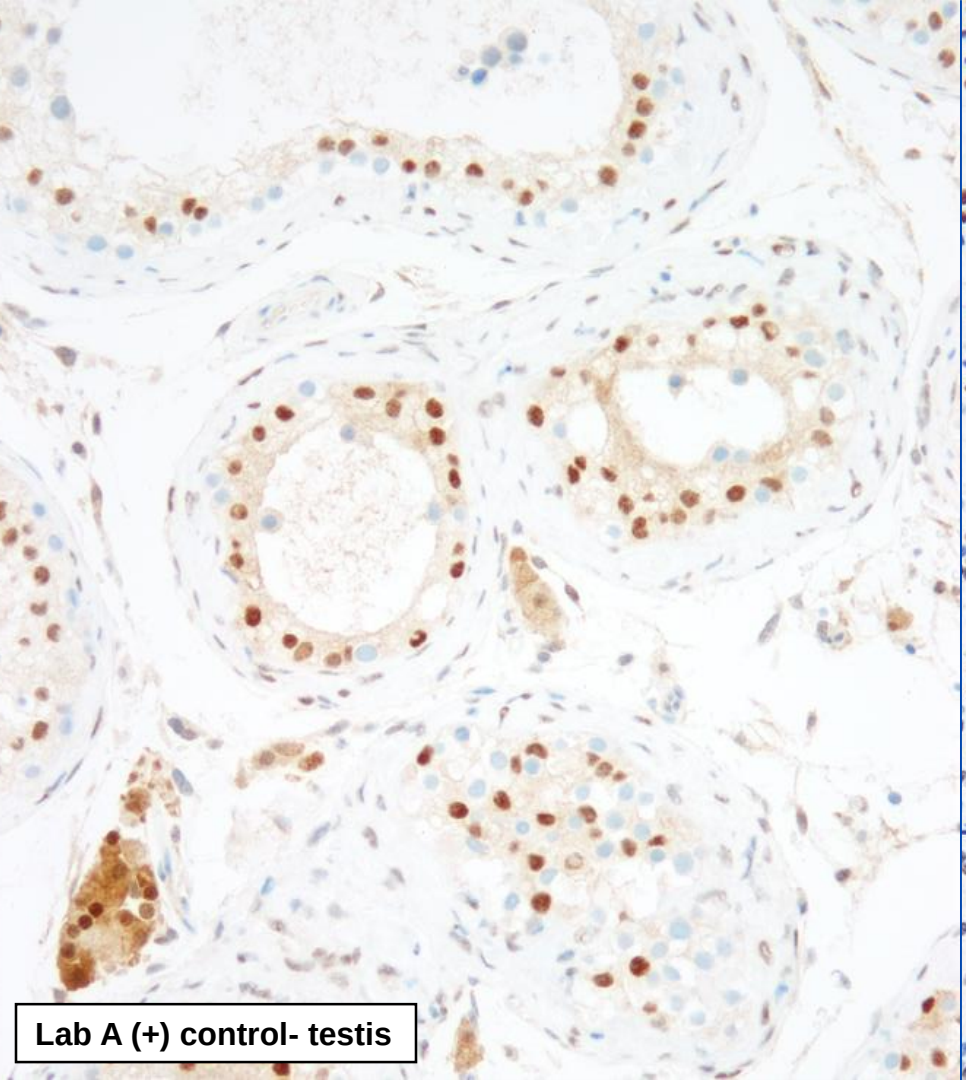
Lab A (+) control- testis

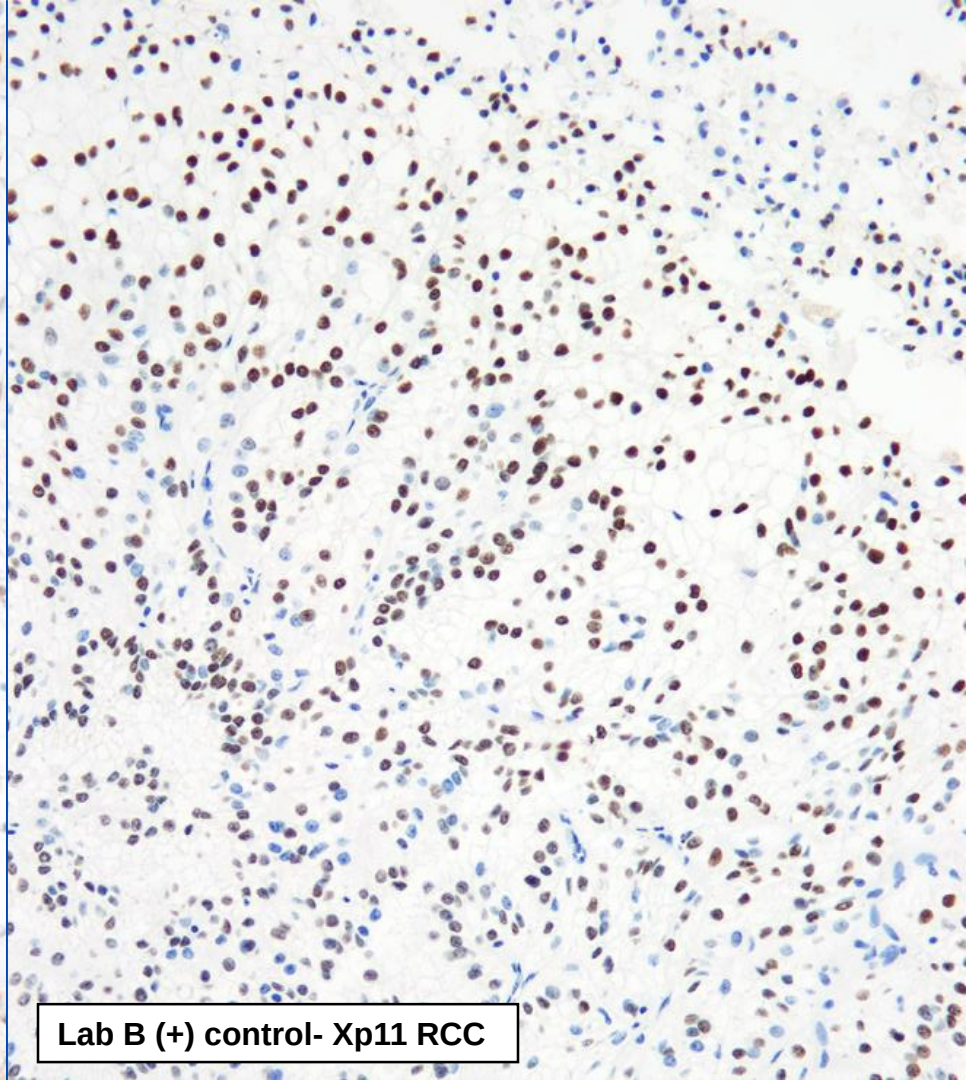
Lab B (+) control- Xp11 RCC

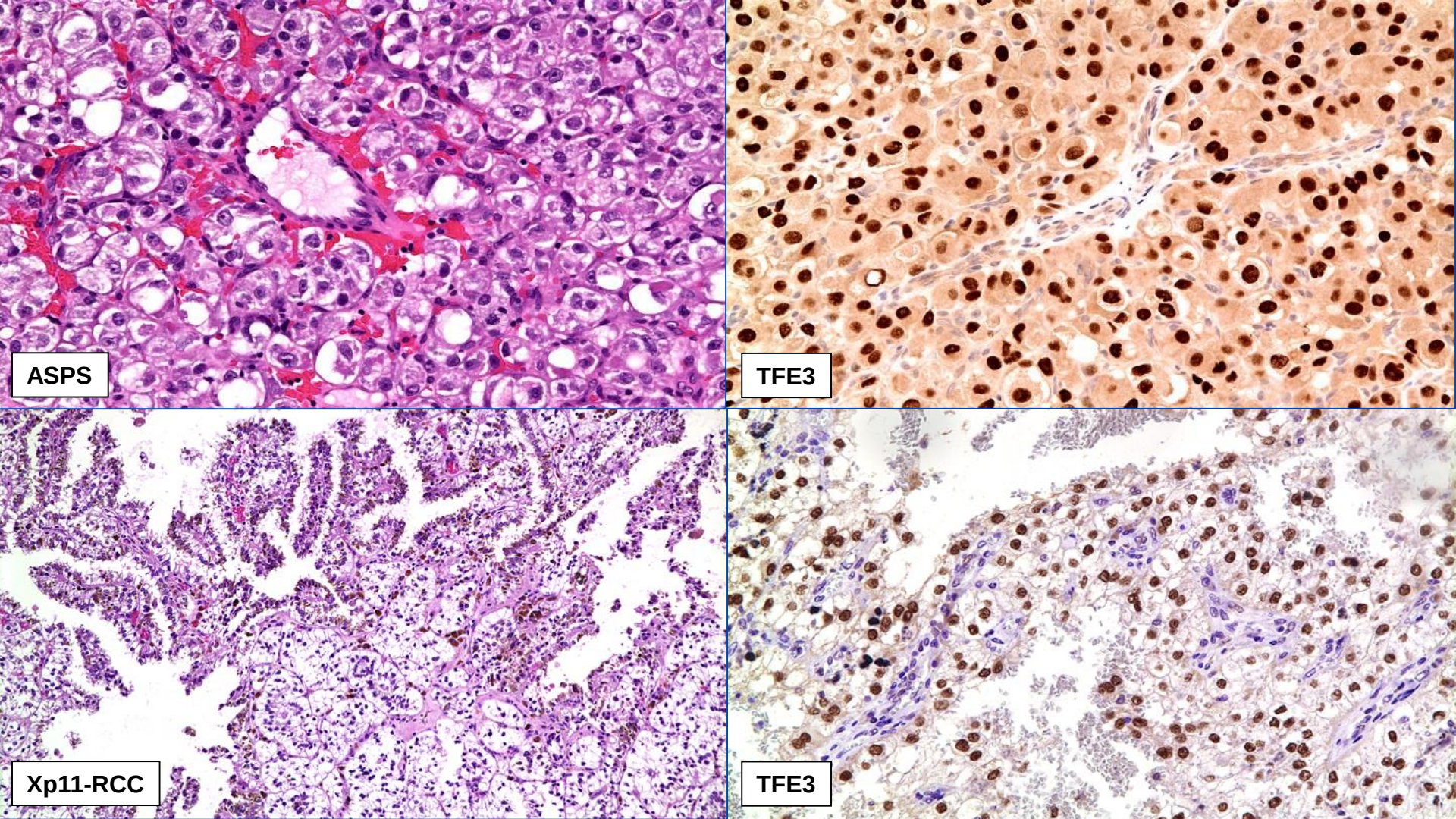
ASPS
TFE3
Xp11-RCC
TFE3

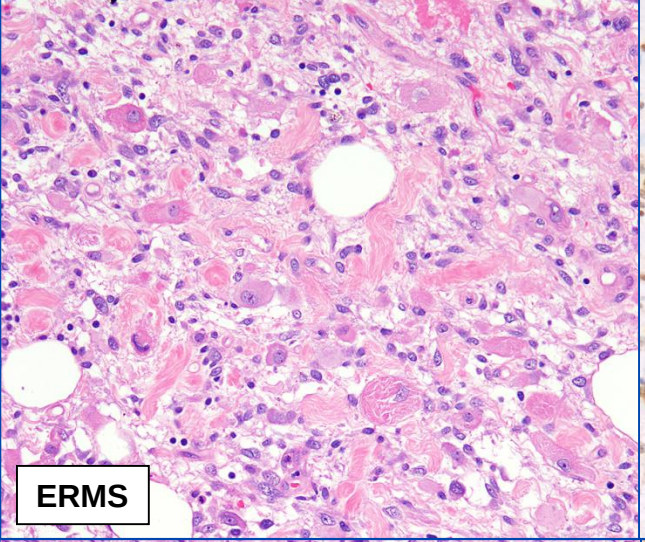
ERMS

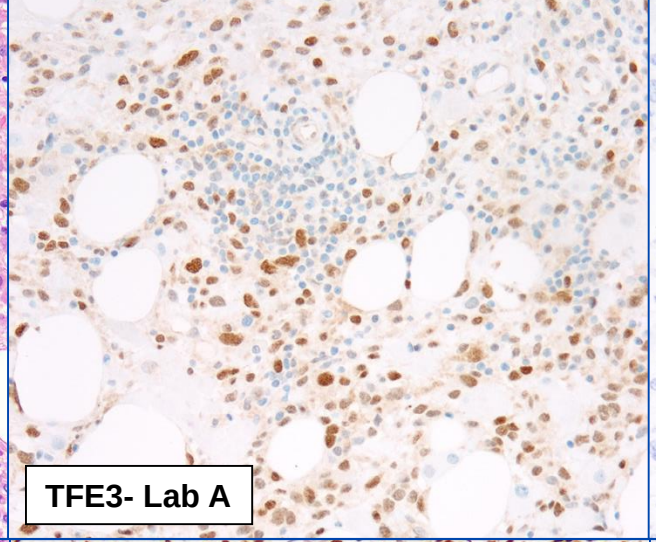
TFE3- Lab A

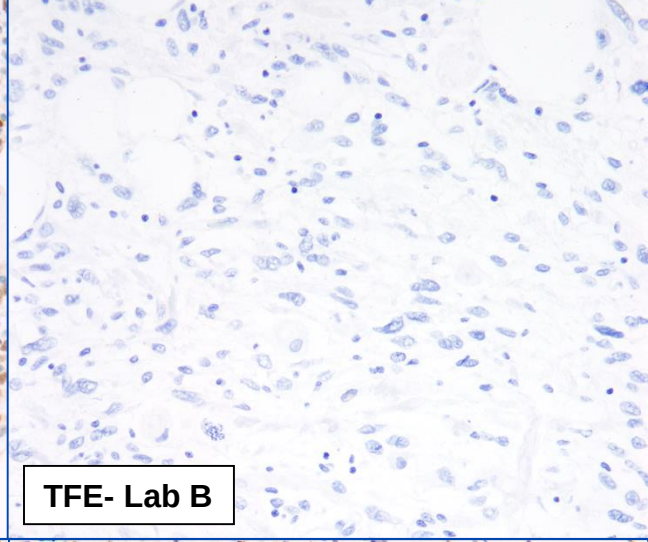
TFE- Lab B

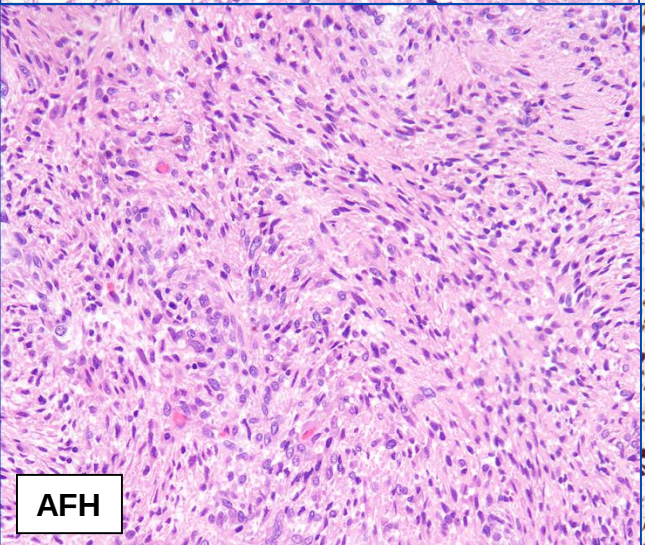
AFH

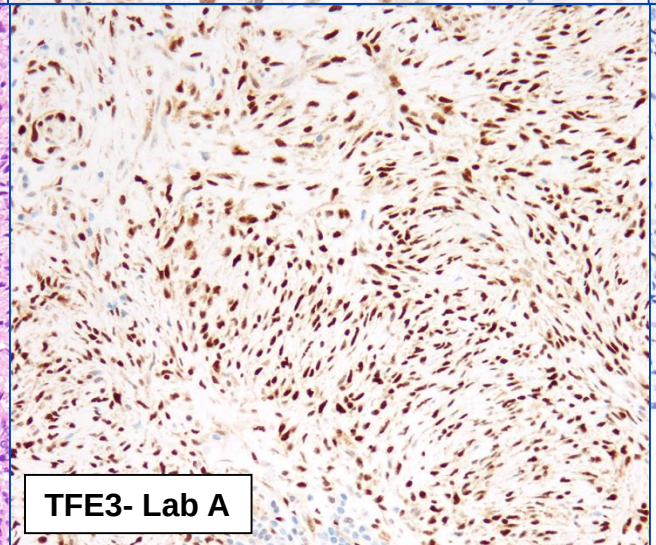
TFE3- Lab A

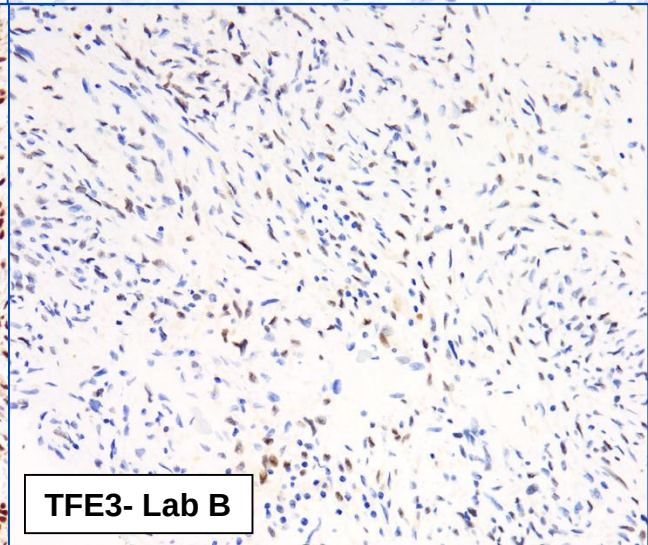
TFE3- Lab B

Conclusions

- A variety of newly developed immunohistochemical markers may serve as valuable adjuncts in the diagnosis of soft tissue tumors harboring specific molecular alterations
- As in any other area of immunohistochemistry, these new markers must be used as part of a panel of antibodies, and interpreted in the overall clinical and morphological context
- Some surrogate IHC markers of underlying genetic events may ultimately prove superior to molecular techniques (e.g., MUC4 and BCOR)
- The specificity of some markers (e.g., TRK) remains to be determined
- Others lack specificity (e.g., TLE and TFE3) and are likely to “fade away” with the increasing availability of molecular genetic testing

©2016 MFMER