31st European Congress of Pathology

Pathology is Nice

7–11 September 2019, Nice, France

European Society of Pathology

Histopathology and DNA evaluation of wet specimens from the Pathology Collection of Turin

Luisa Ferrari1,2
Jasna Metovic2, Daniela Rullo3, Daniela Pulcinelli4, Antonio Lombardi4, Franco Papola4 and
Luca Ventura3

1 Division of Pathology Cardinal Massaia Hospital Asti 2 Departments of Oncology Pathology Unit University of Turin Torino 3 Division of Pathology San Salvatore Hospital L'Aquila 4 Regional Centre of Immunohematology and Tissue typing San Salvatore Hospital L'Aquila

The authors declare no conflict of interest

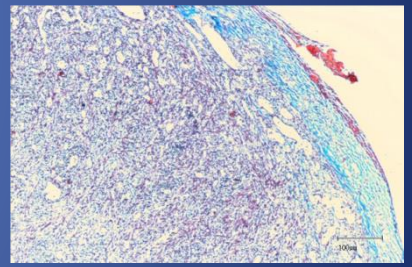

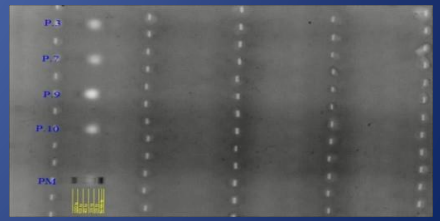

The Pathology Collection of Turin houses around 300 wet specimens dating back to XIX-XX century



Most of these specimens are in their original jars with labels describing year, necropsy number and original old diagnosis.

Due to their original conditions these specimens are an actual

biological archive

and may represent a valid source for research on molecular features of ancient diseases.



Four cases originally diagnosed as

lung cancer
uterine myosarcoma
pleural sarcomas (2)

underwent modern diagnostic revision and DNA evaluation by conservative sampling.

Case 1: Lung cancer

Case 2: Uterine Myosarcoma



Case 3: Pleural sarcoma (1896)



Case 4: Pleural sarcoma(1898)

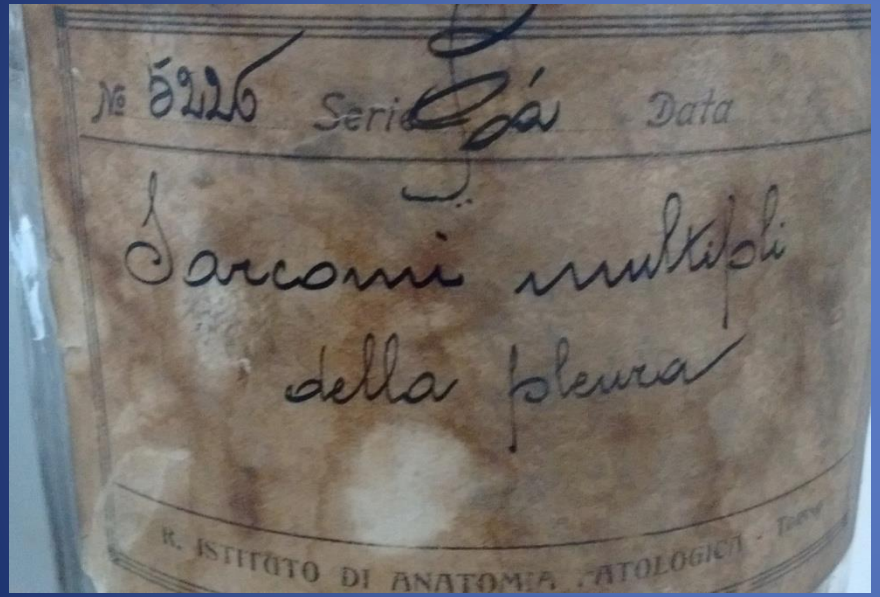

Samples from the specimens were submitted to routine histology, histochemistry and immunohistochemistry.

A research was carried out on autopsy report to identify autopsy findings and clinical history.

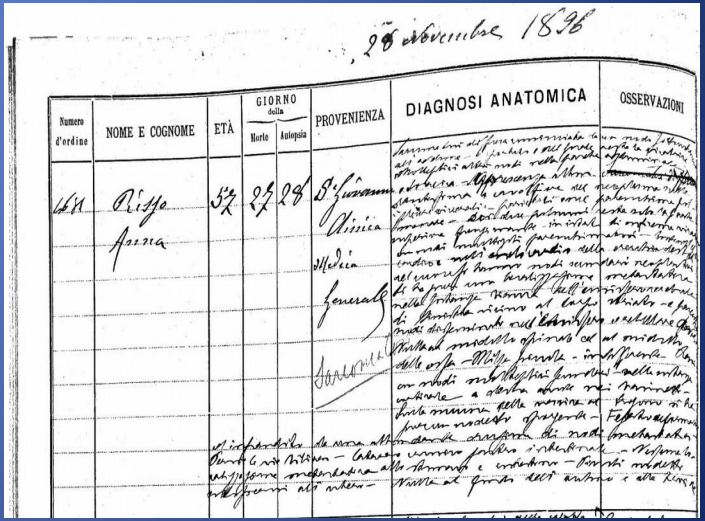

28 Novembre 1836

Numero d'ordine	NOME E COGNOME	ETÀ	GIORNO della Morte	GIORNO della Autopsia	PROVENIENZA	DIAGNOSI ANATOMICA	OSSERVAZIONI
641	Rizzo Anna	52	27	28	S. Giovanni Clinica Medica generale		

The revised diagnoses were:

- necrotic lung carcinoma
- uterine leiomyosarcoma
- lung metastases from squamous carcinoma of unknown primary
- lung metastases from uterine leiomyosarcoma

Lung metastases of squamous carcinoma of unknown primary

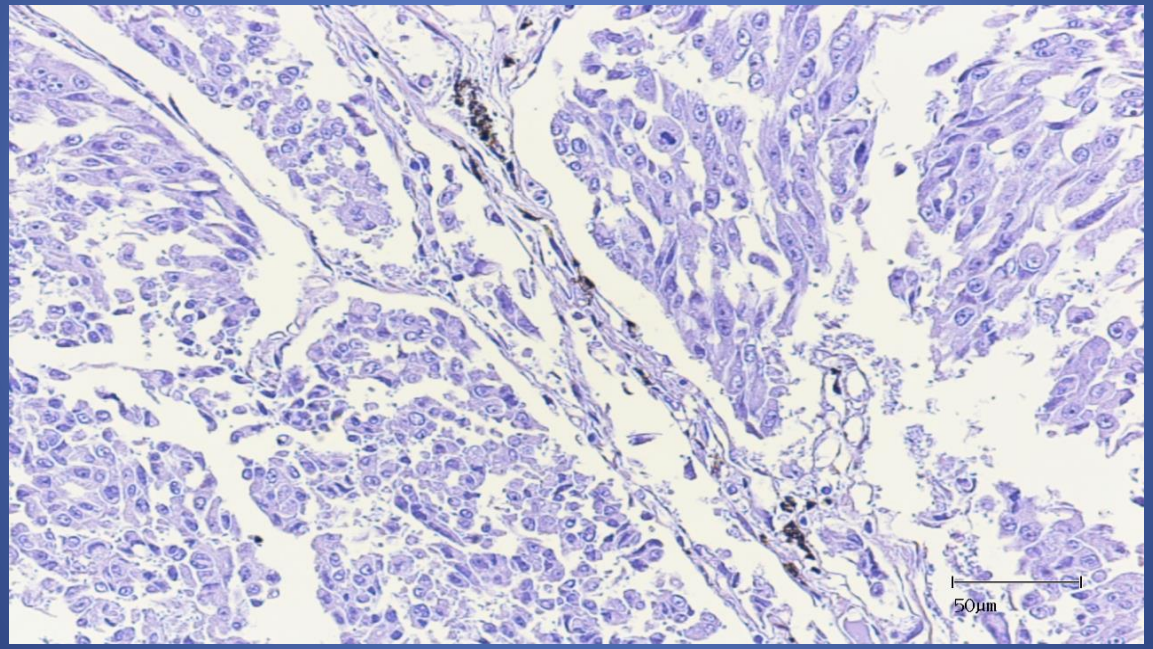

Reticular fibers staining

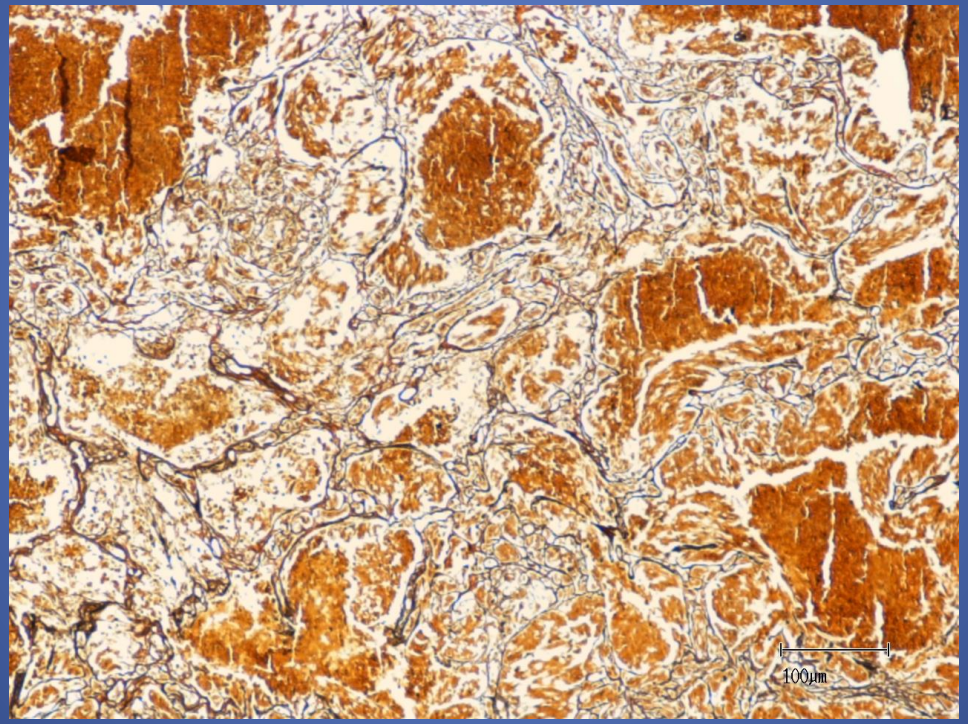

Alcian blu staining

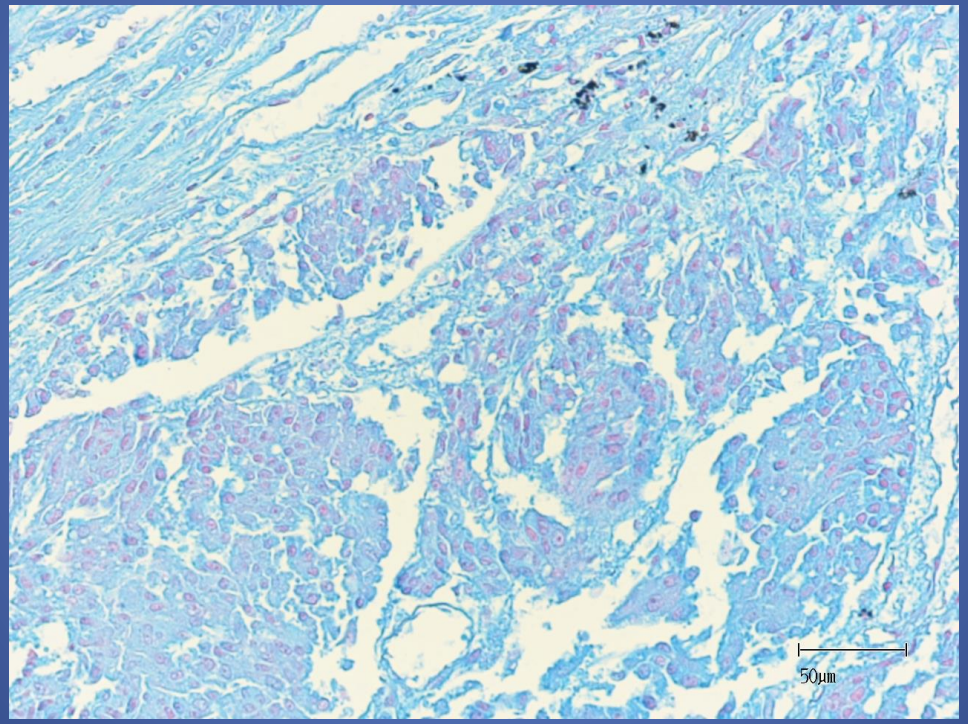

Lung metastases from uterine leiomyosarcoma

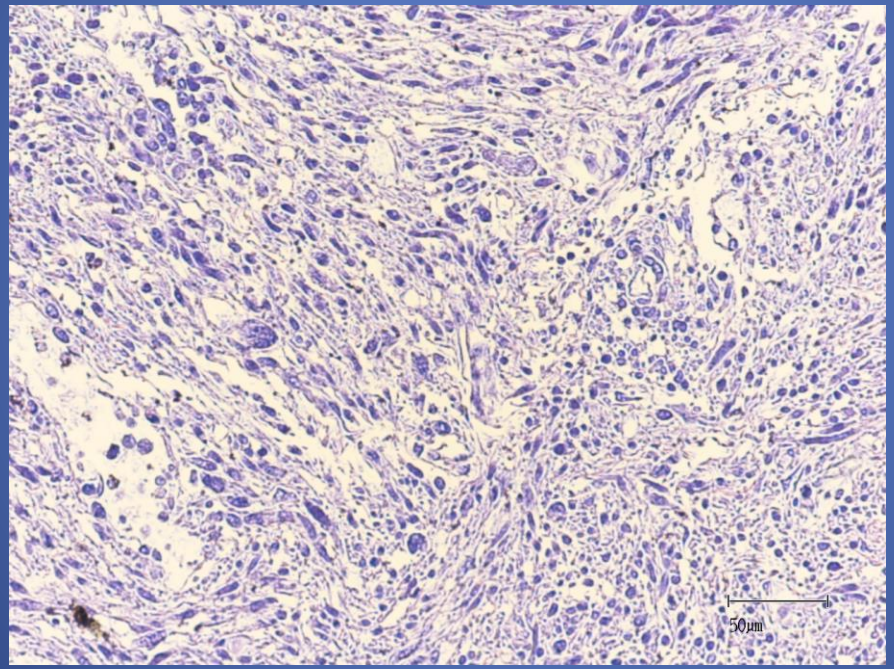

Trichrome stain

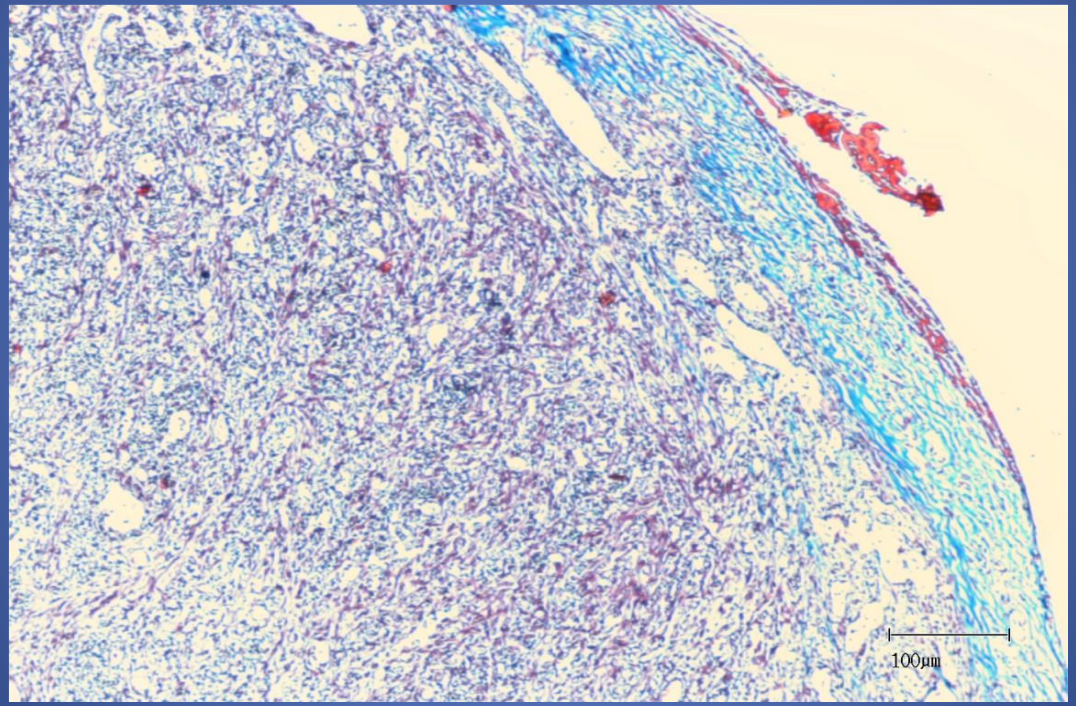

Cytokeratin MNF116

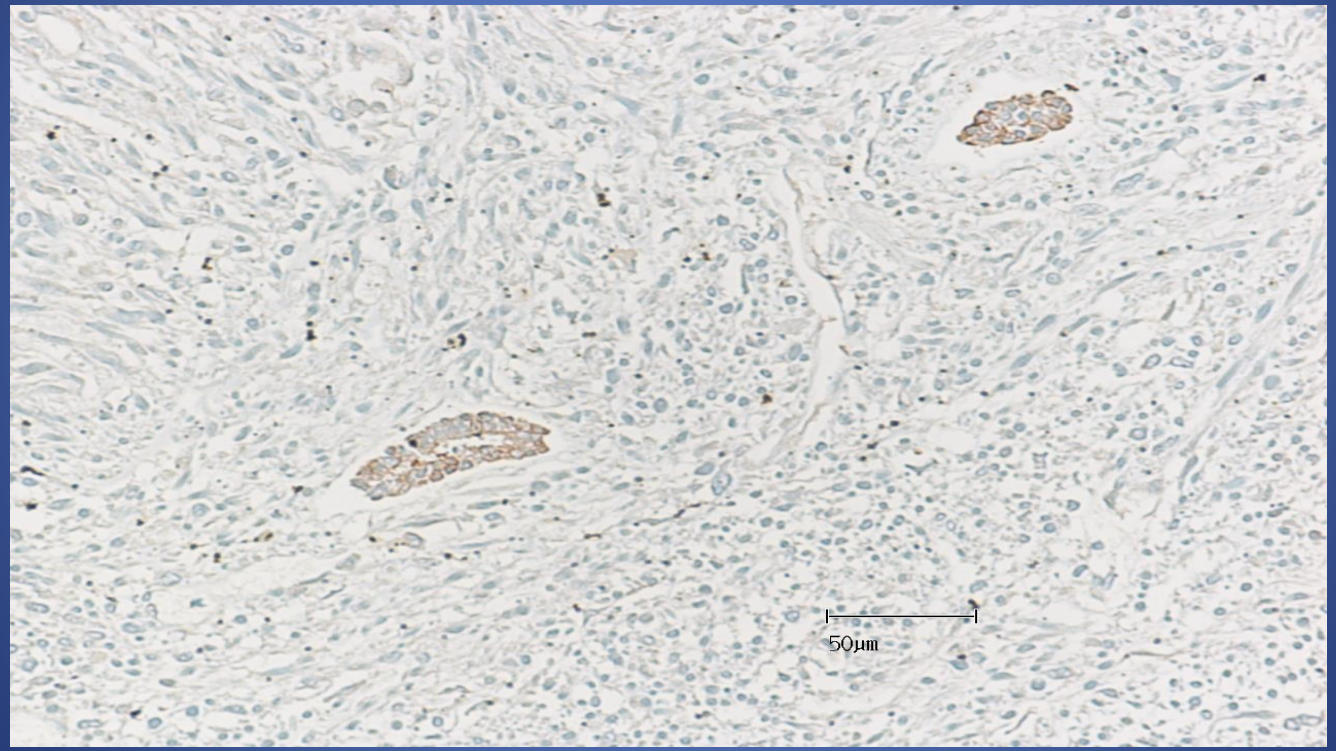

Additional tiny samples underwent DNA extraction and analysis by spectrophotometry and electrophoretic run in agarose gel.

As the chemical composition of the storage fluids is unknown, pH value was measured in each specimen.

pH values were

- 2.56 necrotic lung carcinoma
- 3.15 uterine leiomyosarcoma
- 4.45 lung metastases from squamous carcinoma of unknown primary
- 4.65 lung metastases from uterine leiomyosarcoma

The samples were taken by conservative method and cryostatic sections (-20 degrees C) were obtained 10 microns thick.

Digestion of the section with solution of 75 mM NaCl, 10 mM tris, 0.5 mM EDTA to pH 8.0 and 100 ml of K Proteinase solution. (18 mg/ml)

The samples were incubated at 56 degrees C for 48 hours

50 ml of fresh K Proteinasi solution was added for 72 hours

400 ml of solution was then extracted (magnetic beads -Roche MAGNA PURE COMPACT instrumentation)

DNA quantity were assessed using the entire absorption spectrum (220/340 nm) obtained from the Nanophotometer P 300 spectrophotometer.

The concentration of DNA in ng/ml and absorption at 260/280 nm were evaluated on 4 ml samples.

Gel electrophoresis

agarose at 1.3%

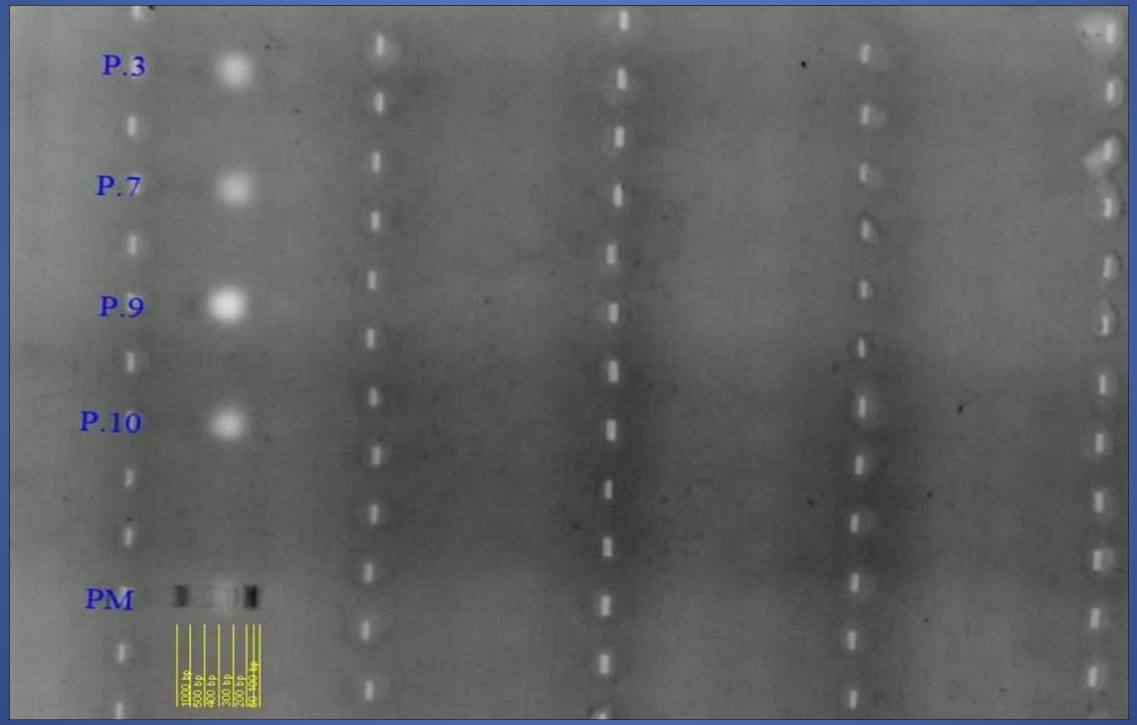

RESULTS

The first two samples gave negative results on both spectrophotometric and electrophoretic analysis

Case 3 – pH 4.45

spectrophotometric analysis absorbance 1.53 6ng/ml

Electrophoretic analysis DNA band with molecular weight about 400bp

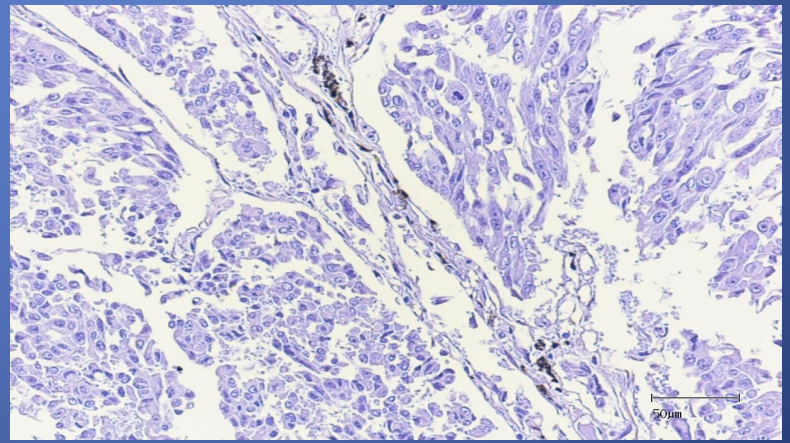

Caso 4 - pH 4.65

Spectrophotometric analysis absorbance 1.50 7ng/ml

Electrophoretic analysis DNA band with molecular weight about 500bp

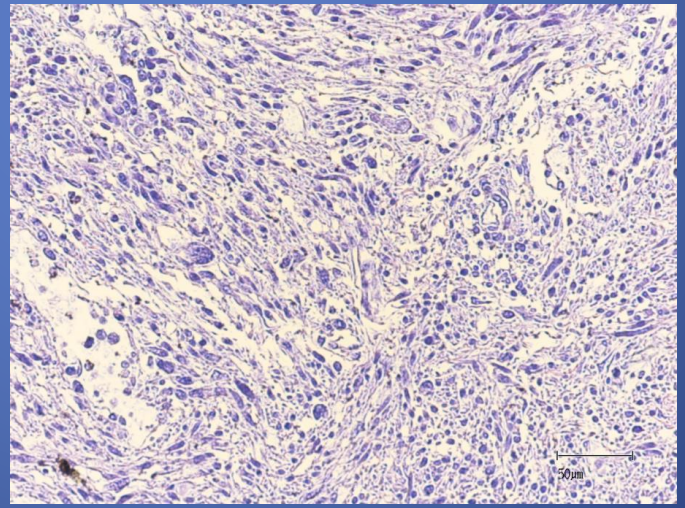

To assess DNA integrity, short tandem repeat (STR) analysis with PowerPlex 16 HS (PROMEGA) panel employed for personal identification was used

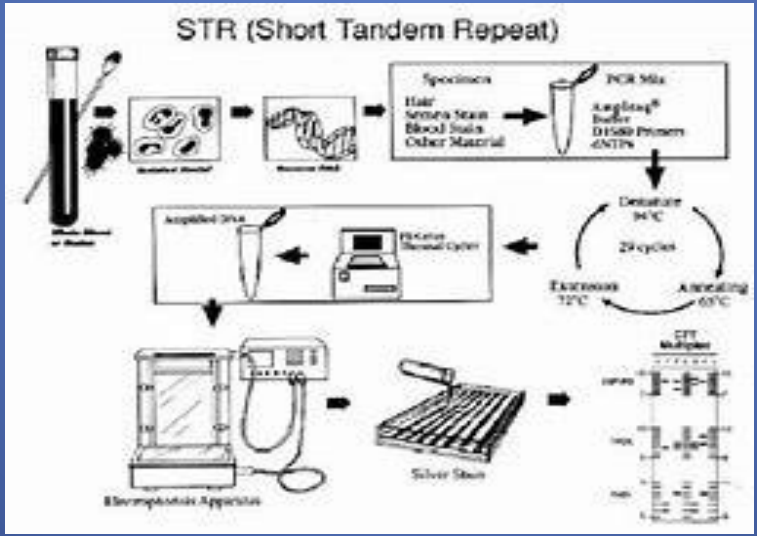

The amplification of amelogenin STRs of chromosome X demonstrates the probable presence of a female subject in case 3

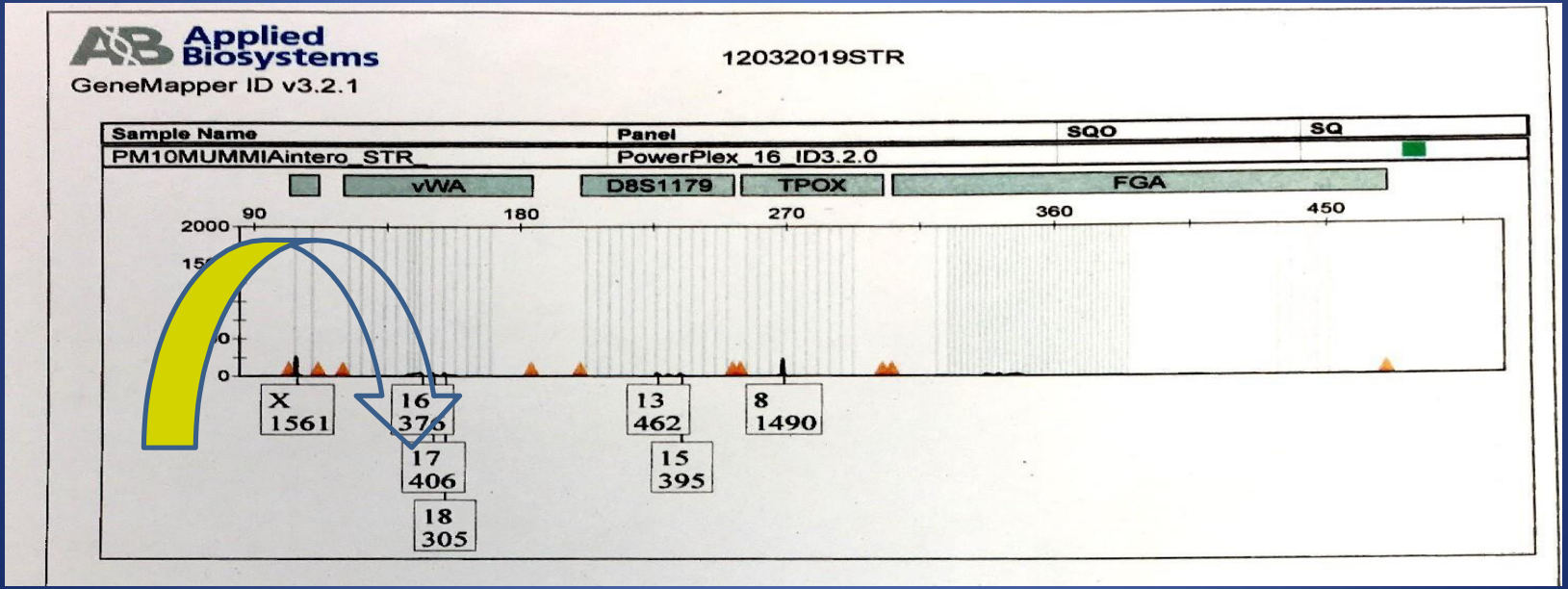

This allowed us to identify the most probable autopsy report

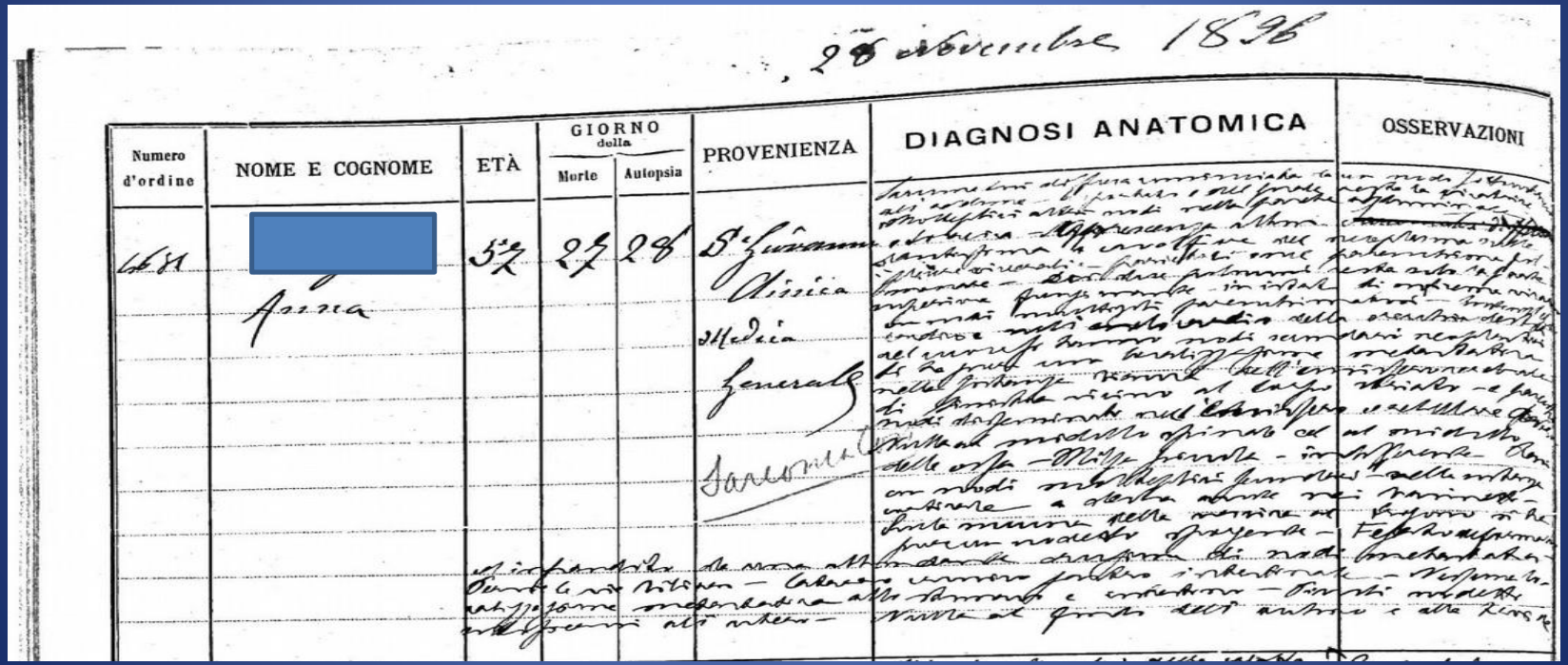

28 novembre 1896

Numero d'ordine	NOME E COGNOME	ETÀ	GIORNO della Morte	GIORNO della Autopsia	PROVENIENZA	DIAGNOSI ANATOMICA	OSSERVAZIONI
681	[redacted] Anna	57	27	28	S.a Giuseppina Clinica Medica Generale		

CONCLUSIONS

This study confirms the importance of Pathology Collections as a

historical archive of

diseases that no longer exist or with natural course unmodified and also as

biological archive

Pathology Museums must be preserved as a precious historical and biological heritage!!



Thanks for your attention!